

Neuropsychological Rehabilitation in a Case of Dynamic Aphasia

Yulia Solovieva^{1*} and Luis Quintanar¹

¹*Faculty of Psychology, Puebla Autonomous University, Mexico.*

Authors' contributions

This work was carried out in collaboration between both authors. Author YS designed the study, performed the statistical analysis, wrote the protocol and wrote the first draft of the manuscript. Authors LQ and YS managed the analyses of the study. Author LQ managed the literature searches. Both authors read and approved the final manuscript.

Article Information

DOI: 10.9734/INDJ/2018/42633

Editor(s):

(1) Manabu Makinodan, Assistant Professor, Department of Psychiatry, Nara Medical University, Japan.

Reviewers:

(1) Lucia Iracema Zanotto de Mendonça, Pontifícia Universidade Católica de São Paulo, Brasil.

(2) Okonkwo Uchenna, Nnamdi Azikiwe University Awka, Nigeria.

(3) Alessandra Pereira Lopes, Faculdades Integradas Maria Thereza, Brazil.

(4) Karin Zazo Ortiz, Universidade Federal de Sao Paulo, Brazil.

Complete Peer review History: <http://www.sciencedomain.org/review-history/25855>

Original Research Article

Received 1st June 2018
Accepted 5th August 2018
Published 11th August 2018

ABSTRACT

Dynamic aphasia is considered to be a rare neuropsychological syndrome. Reports of cases of dynamic aphasia aren't so frequent in literature. The objective of this work is to show the effects of the program for neuropsychological rehabilitation in a case of an adult patient with dynamic aphasia. The patient was a young left-handed woman who suffered bilateral damage in anterior cortical regions as a result of traumatic brain injury. The qualitative neuropsychological assessment established a clinical syndrome of dynamic aphasia (according to the classification proposed by A.R. Luria) together with severe spatial difficulties. The content for the neuropsychological program was created and applied 3 times per week during the period of 4 months, with the total of 40 individual sessions. The tasks of the program were carried out on different levels of actions, including material, perceptive and verbal levels. The guided activities were used during the work of rehabilitation. Therapist has always provided all necessary orientation, while the execution was divided between patient and the therapist. Examples of execution of tasks of neuropsychological assessment are presented before and after the work with the program. The results pointed out essential changes in speech production of the patient together with successful execution of tasks for

*Corresponding author: E-mail: yulia.solovieva@correo.buap.mx;

visuo-spatial orientation. Positive changes were noticed in emotional sphere of the patient as she started to communicate in her family. High possibilities of neuropsychological rehabilitation together with neuroplasticity should be considered in cases of brain injury. We conclude that neuropsychological rehabilitation created on solid theoretical bases may improve significantly the level of life and social activity of patients with brain damage.

Keywords: Brain injury; dynamic aphasia; neuropsychological assessment; neuropsychological rehabilitation; programs for rehabilitation.

1. INTRODUCTION

Dynamic aphasia is one of the types of aphasia according to the classification proposed by Luria [1]. This classification includes seven types of aphasia: motor efferent aphasia, motor afferent aphasia, sensory aphasia, amnesic aphasia, acoustic-amnesic aphasia, semantic aphasia and dynamic aphasia.

Cases of dynamic aphasia are not so frequent in clinical practice, and cases of results of neuropsychological assessment together with results of rehabilitation were not reported in Spanish speaking patients. Clinical analysis of such cases is complex and requires of detailed consideration of linguistic levels of Spanish language.

Patients suffering from 'dynamic aphasia' normally show markedly reduced spontaneous speech despite well-preserved basic language skills [2,3]. The first author who described such kind of alteration was Lichtheim [4]. This author has noticed that the conceptual system was disconnected from the language system in the patient. For similar cases, Kleist [5] used the term 'Adynamie der Sprache' as examples of the absence of dynamic speech in the patients after brain damages.

Similar features of the absence of dynamic speech production were found in cases of progressive supranuclear palsy [6,7, 8], dementia [9], parkinsonism [10]. Some authors called dynamic aphasia as a kind of transcortical motor aphasia [11,12,13,14] or as one of the kinds of non-fluent aphasia [15].

Known works of Luria [1,2] and his followers, who studied cases of patients with dynamic aphasia, have pointed out the absence of subject's own initiative to take part in communicative verbal acts. The patients were able to answer the questions briefly, only by some short phrases and isolated words, but were unable to produce or organize long sentences.

The articulatory aspects and phonological analysis of language were always well preserved. The patients were always able to repeat words, phrases and even sentences during the assessment. The main difficulty was own initiative of the patients for oral speech and written production.

According to classification of types of aphasia proposed by A.R. Luria [2,16,17], the central mechanism of dynamic aphasia is a deficit of inner speech of the patients. Frequently, such kind of disturbances is a consequence of anterior cortical lesions including posterior frontal zones.

The patients with dynamic aphasia, described by Luria and his followers [2,16,17], never present any kind of secondary motor or sensorial difficulties. These patients managed to name presented concrete objects and to recognize concrete images and pictures. According to descriptions, patients with dynamic aphasia normally preserve spatial orientation and they can draw and copy simple images and words. They didn't show apraxia, neither agnosia. These patients could only respond to the questions directed to them with short answer consisting of two or three simple words. The patients used to repeat words and phrases of the questions in their answers. They were unable to include any new words, phrases or expressions in their answers. The patients were unable to establish any communication with other people because of the absence of own initiative. A.R. Luria has described such patients with such terms as "adynamia of nervous processes" or "absence of verbal activity".

Another possibility of explanation of such verbal difficulties would be absence of proper initiative for verbal communication as a consequence of brain damage. Such behavior always contrasted with features of personality and activity of the patients in their day-to-day life before the accidents.

Luria has proposed and approved the ways for descriptions of clinical picture of dynamic aphasia together with strategies of neuropsychological rehabilitation was founded by Luria and his school [2,16,17].

It is important to notice that Luria's contribution to neuropsychological assessment of patients with aphasia excluded psychometric methods and statistical analysis of the data. The methods of clinical qualitative testing were developed and proposed for Russian speaking patients in the works published by Luria [2,16,17]. The data of such qualitative assessment permitted to establish the central mechanism of dynamic aphasia as "speech adynamy" or poor verbal communicative initiative. These findings always served as the basis for future rehabilitation, which was focused on re-organization of communicative activity and stimulation of verbal initiative proposed by therapist in individual sessions. Positive results of such neuropsychological treatment were communicated in diverse publications [2,16,17].

In Luria's historical cultural model, the treatment is directed to the cause of patient's difficulties and to improvement of communicative activity in contrast with the treatment of isolated cognitive functions, pharmacological treatment [18,19,20] or behavioral management [21,22,23].

It is possible to suppose that one of fundamental principles of neuropsychological rehabilitation of dynamic aphasia is that guided stimulation of damaged neural networks in communicative situations allows faster and more accurate language processing [24, 25]. Some models of parallel language processing in artificial intelligence systems support this assumption [26].

According to some theoretical positions of Luria's conception [2], it is possible to suppose the presence of some specific difficulties with different kinds of intellectual actions in cases of dynamic aphasia. Such actions might be written production of patients with dynamic aphasia. Written speech is too difficult task for such patients and requires verbal initiative and proper organization at the level of complex coherent text. On the contrast, copy is accessible for patients, as it frequently represents only reproductive operation.

Other severe difficulties with verbal tasks might be also found, such as grammar and lexical

operations [17]. Comprehension of complex verbal texts and the realization of complex logic and intellectual tasks are other examples of difficult tasks for the patients with dynamic aphasia. They are unable to fulfil all the mentioned tasks by themselves. External help is usually helpful and offers an important possibility for successful rehabilitation [27]. Such difficulties might be similar to those of the patients with frontal lesions with primary difficulties with programming and control and without any kind of aphasia. It would be possible even to consider that dynamic aphasia is a kind of a variant of a mild frontal syndrome. The difference is that normally, the patients with primary difficulties in programming and control are unable to fulfil intellectual tasks even after external help [2].

In particular cases of aphasia as a consequence of brain injury, it is difficult to propose generalized treatments. Each type of aphasia includes specific brain mechanisms, which might be affected by different manners. Participation of brain cortical mechanisms requires precise methods of neuropsychological assessment. Qualitative neuropsychological assessment might detect central mechanisms in each case of aphasia, which isn't often used by specialists. Unfortunately, specialists in clinic neuropsychology don't take part yet in interdisciplinary teams for assessment of patients and detailed diagnosis [28]. Quantitative methods of assessment don't permit to identification of the central mechanisms in cases of aphasia.

2. OBJECTIVE

The objective of this work is to present the effects of neuropsychological rehabilitation as a case study of young female left handed patient who suffered bilateral brain injury and received a diagnosis of dynamic aphasia.

2.1 Case Analysis

The method of our study is a method of clinical "Case Study" of unique patient based on qualitative neuropsychological assessment by presentation of specific tasks during interaction with therapist [2,11,14].

Neuropsychological qualitative assessment took place before and after participation of the patient in the program of neuropsychological rehabilitation. The rehabilitation program was designed and applied by therapeutic work with the patient in individual sessions during a period

of four months. Both assessment and rehabilitation were accomplished within the Program of Neuropsychological Diagnosis and Rehabilitation of Faculty of Psychology of Puebla Autonomous University. The patient assisted the clinic of University Hospital of Puebla Autonomous University as a participant of social service. The patient herself and her family were highly interested in the process of neuropsychological rehabilitation and have signed their agreement for assessment and treatment.

The young female patient, 21 years old, left handed, student of the first semester of Physical Rehabilitation was included in the study. The patient suffered severe brain damage in a traffic accident in anterior cortical left region. Computed axial tomography revealed damage in left frontal and temporal regions with contralateral uptake and subcortical participation of medial zone. EEG study applied to the patient permitted to conclude bilateral cortical frontal affectation, both on cortical and subcortical level.

2.2 Initial Neuropsychological Assessment

Neuropsychological assessment was carried out three months and a half after the accident. The assessment was applied in eight individual sessions of one hour each. After completing initial assessment, the program of neuropsychological rehabilitation was created and applied in forty individual sessions of one hour each during four months. Finally, after the work with the program or rehabilitation, another neuropsychological assessment was applied and the qualitative results were compared with the data of initial assessment.

Protocols for Brief Neuropsychological Assessment for Adults [29] and Neuropsychological Assessment for Patients with Aphasia were used during initial assessment [30]. The first of the mentioned protocols evaluates functional stage of neuropsychological mechanisms such as regulation and control, motor sequential organization, spatial, kinesthetic and phonological integration. The second protocol permits to establish specific form of aphasia.

During initial assessment, the patient wasn't able to remember or express any details occurred after the accident, so the effects of post traumatic amnesia were present during initial assessment. As the consequence of severe brain injury, the

patient lost the capacity of oral expression and orientation in space and time. The primary motor sphere was strongly altered; the patient wasn't able to walk and used the stroller. The patient presented paresis in her left leg and hand. Emotional expression was totally plain, the patient refused to use bath, to go to the toilet, to eat and to interact with parents including her own daughter.

Initial Neuropsychological Assessment pointed out conservation of the following mechanisms of patient's activity: phonemic and phonemic discrimination, motor organization of praxis, kinesthesia perception, programming and control of voluntary activity and elementary retention (memory) in all modalities: tactil, auditive and visual. Comprehension and repetition of common isolated words and direct sentences including orders were preserved.

Important difficulties were found with oral and written production. The patient wasn't able to start her verbal production by herself; she was inactive and had no initiative for verbal communication; facial expression was poor. All such data permitted to assume the absence of verbal initiative which unabled patient's verbal communication as the central defect of dynamic aphasia, described by Luria [2]. The Table 1 shows an example of oral answers of the patient to the questions in a dialogue.

Table 1. Narrative task during assessment


Narration: What have you done yesterday?

1. Indifferent gestures and no answer.

Are you interested in something you can tell me?

2. "Something "

Additionally, serious difficulties were also observed in all tasks, which included spatial orientation. The tasks for assessments of visual and spatial orientation were selected [30, 31]. These tasks included complex intellectual logic actions, which were applied on concrete, perceptive and verbal levels [32, 16, 33]. The tasks included logic sequences, classifications, reading and understanding of texts and sentences, proverbs, elaboration of plans for texts, problem solutions, selection of titles for texts and analysis of artistic paintings [34, 35, 36]. The patient showed sever difficulties in all tasks, which included spatial orientation. At the same time, the patient has no primary difficulties in logic or intellectual tasks, where she had to show the right answer between given



A. Model

B. Execution of the patient

Figure. 1. Rotation in constructive task during initial assessment

options and in the tasks free of spatial relations between the elements of the task.

It is interesting to notice, that the patient was able to understand sentences and phrases with spatial and temporal prepositions, but she wasn't able to copy any figure, rotation and absence of spatial orientation was detected in all constructive tasks (Figure. 1). The patient's construction shows the clear presence of spatial rotation of the model.

Results of qualitative assessment permitted to conclude predominant syndrome of dynamic aphasia together with severe difficulties in spatial orientation.

2.3 Neuropsychological Rehabilitation Program

The program of neuropsychological rehabilitation was created on the basis of theoretic and methodological proposals of Luria's neuropsychological approach, which consider central mechanisms of each patient with aphasia [34,35,36]. In our patient, central mechanisms were related to the absence of verbal initiative together with strong difficulties with spatial orientation. All tasks of rehabilitation were directed to progressive development of these two weak mechanisms.

All tasks were presented in every session with modified content but same structure and purpose of the tasks. All tasks were presented with external verbal and non-verbal help and explanation of the therapist.

2.4 Stages of Neuropsychological Rehabilitation

Stage 1

Objective: To re-establish visual image with support of verbal oral initiative for communication and programming of language production.

2.4.1 Main tasks

1. The tasks for completing of images of concrete objects; completing of half parts of images, selection of missing parts of images; selection of correspondent images according to a variety of external shapes. Firstly, symmetric figures were presented, later on the patient started to work with more complex asymmetric images.
2. Work with thematic series of picture and cards. The patient had to listen carefully to oral description of actions and details of pictures and tried to complete (verbally) some phrases correspondent to the pictures by herself. The therapist had to help the patient all the time by presenting oral examples and initial parts of phrases. Firstly, pictures with small quantity of details were presented; later on, the pictures became more complex.
3. Work with spatial positions of images. The patient had to determine correct positions of images according to different alternatives. On that purpose, the images were presented in different options of wrong and correct spatial position. The visual stimuli became more complex during the progress of the patient.

4. Work with super located images. The patient had to select and to name the images with the help of the therapist.
5. The work with a big piece of paper, in which the patient had to "form" different figures and geometric shapes with the help of external "points".
6. Selection of shapes for images. The patient had to select the appropriate shapes for different objects and figures. The visual stimuli became more complex during the progress of the patient.
7. Different kinds of constructive tasks. The models with analysis of all positions and details were constantly used during the work.
8. The patient became more independent during this work, as she presented more initiation and more interest according to her own success.

Stage 2

Objective: to re-establish written language. The external language of the therapist was constantly used as orientation at this stage.

2.4.2 Main tasks

1. Drawings of shapes and objects. Different geometric shapes and figures were drawn on the floor. The patient had to follow the movement of her hand with the eyes to obtain the same shape and to draw it independently. Later on, same shapes were drawn on the paper or on the blackboard. The patient had to express her movements and to name all the shapes orally. Afterwards, she was asked to put down the name of the shapes.
2. Work with the shapes of the letters. Same procedure was offered with shapes of letters. Different sizes of capital and small letters were used, starting from the biggest size.
3. Work with proportions of elements of letters. The patient had to mark letters, which don't differ in the positions in relation to the base line: *m, s, o, r*, etc. Later on, letters with changes of the basic position are included: 1) *p, q, y, g*; 2) *d, h, l, t, b, k*, etc. The patient has to mark the letter, which were higher or lower than the letters, which occupied only the basic line.
4. Work with structure of the words. The patient had to write each letter of the word on the red line, inside the square for

marking the limits of letters. The line and the square were drawn firstly by the therapist and later by the patient herself. Firstly, the patient could only make the copy of the letters and words. Later on, she started to work independently.

5. Drawing of constructed objects. The patients had to construct different objects according to presented models. After construction, she was asked to draw the objects on paper according to the basic coordinates.

Stage 3

Objective: to re-establish oral expression.

2.4.3 Main tasks

1. Production of sentences with the help of content of thematic series and pictures. In these tasks, the therapist was the one who always presented a verb, while the patient had to complete the sentences with the nouns and other grammar categories. The patient had to establish different logic and grammar connections for the same word and to use it in different contexts (for different pictures).
2. Elaboration of sentences according to cards with isolated words (nouns) and correction. The patient had to form sentences with the words given by therapist. The words were given in separate cards. In other exercises, the words were written with grammar mistakes (according to Spanish grammar rules). The patient was encouraged to find and to correct mistakes.
3. Elaboration of sentences according to cards with isolated auxiliary words (articles, prepositions) and correction. The patient had to complete phrases using articles, prepositions and conjunctions. Some words are omitted in sentences and the patient has to fill the missing words. Spaces with missing words were marked in order to guarantee constant orientation and help with correct execution.
4. Word order. Some instructions and verbal series were given in cards in wrong order. The patient had to establish and to correct the order of the words in sentences.
5. Creation of own sentences. The patient had to construct the sentence according to thematic pictures. External cards were used for these tasks. The cards were

empty and the objective of the cards was to stress the necessity of the presence of verbal element in the sentence. Each card corresponded to a word inside the sentence.

As alternative, cards with questions were used in order to obtain the whole correct sentences according to picture. The questions were: Who? Where? What? What with? Together with what? Doing what?

The patient became more and more independent in her verbal production during this stage.

3. RESULTS

During the work with proposed tasks, the patient has shown significant changes in her behavior, marked by the appearance of general and verbal initiative and verbal productive oral expressions. The following examples evidence the progress of the patient (Figures 2-7). The tasks of initial and final neuropsychological assessment are presented below. Qualitatively better execution could be noticed in the tasks of final assessment. All executions of the tasks during final assessment show better organization on the paper, better distribution of elements and details

of the images and better usage of the shapes of the objects. It wasn't possible to recognize the drawings and writing produced during initial assessment. On the contrary, the drawing and writing during final assessment are presented correctly.

The Figure. 2 shows the progress in the task of the copy of a graphic sequence. The execution in initial tasks shows a tendency to perseverations and impossibility of following the patron together with the absence of clear shapes of the sequence. After rehabilitation, on the right side of the Figure. 2 we can see better effort to represent the shape of the sequence and the absence of perseverations.

The Figure. 3 shows the changes in the task of copy of a house. In the final task the shape of the house is correct, while it wasn't recognizable in the initial representation.

The Figure. 4 shows the drawing of animals by patient before and after rehabilitation and it is possible to recognize clearly a horse after rehabilitation with better representation of the shape of the animal and the details of the face.




Figure. 2. Copy and continuation of the graphic sequence before and after rehabilitation




Figure. 3. Copy of a house before and after rehabilitation




Figure. 4. Task of the drawing of animals before and after rehabilitation. Example of a "horse"

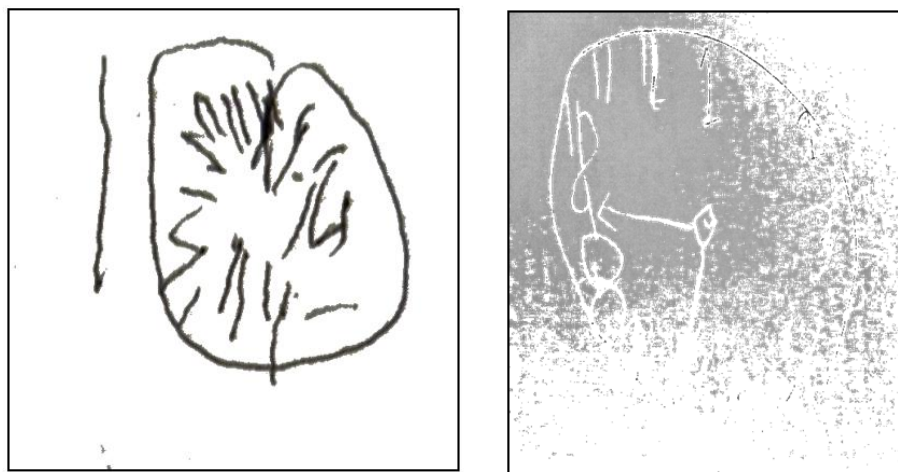


Figure. 5. The drawing of a "watch" before and after rehabilitation

The Figure. 5 represents the drawing of a watch and we can also notice positive changes in the patient's execution. The shape of the watch is much better and the order of the digits are recognizable after rehabilitation. The same situation might be observed in the Figure. 6, where we see the positive drawing of a table after rehabilitation and severe spatial difficulties with the shape of the table before rehabilitation.

The Figure. 7 shows changes in the handwriting of the patient, which wasn't accessible before rehabilitation. After rehabilitation, the patient was able to write letters and words correctly. The lines were marked as an external help for marking the limits of the general shapes of the letter by therapist.

No narration was accessible before rehabilitation (Table 1). The Table 2 shows the oral answer of the patient to the question of the therapist. We can notice that the answer is rather long and coherent.

Another example of oral production is analysis of the content of artistic picture (Figure. 8) by the patient (Table 3). Such complex production wasn't accessible before rehabilitation.

Results of final assessment, in comparison with initial assessment, have shown better distribution of graphic elements of the drawings and handwriting of the patient. It was possible to notice better organization of space and proportions of the images. No rotation or inversion mistakes might be found. Verbal

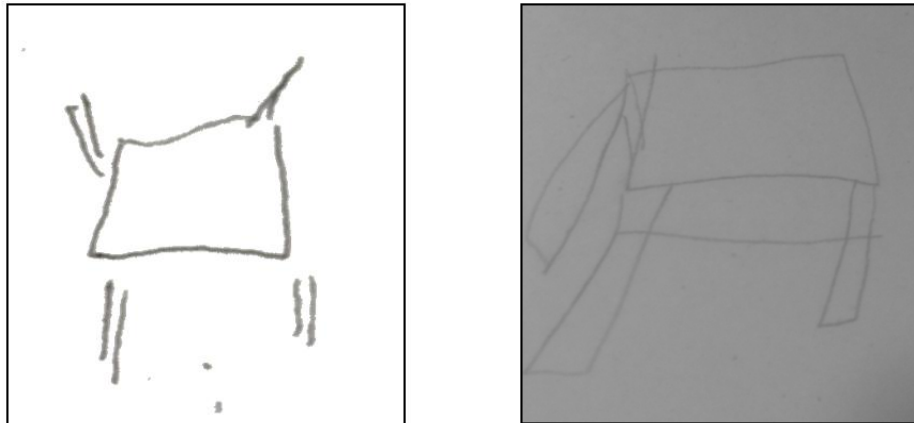


Figure. 6. Drawing of a “table” before and after rehabilitation




Figure. 7. Handwriting before and after rehabilitation

Table 2. Narration after rehabilitation

What did you do yesterday? (Transcription according to answer in Spanish)
<p>“I woke up and got downstairs for breakfast with my mother and my daughter. We had eggs for breakfast. Later I helped my mother to bath Jimena (patient’s Little daughter), and they helped me to bath. My mother took my daughter to school and I stood at home to watch television. After that I eat with my father and my brother and sisters who came to visit me. My sister helped me with my daughter to do home tasks. Next they helped me with `physic therapy, and walked a Little, I get often tired, but I have to look forward, it is for my daughter”.</p>

Table 3. Analysis and work with artistic picture before and after rehabilitation

What can we see on this picture?		
Picture	Initial Assessment	Final Assessment
A girl with basket of flowers.	(Showing a girl) “She is waiting ...”	“This is a picture of an ancient city and there is a girl (shows the girl) who sells flowers with a big basket, may be, she is walking from one pace to another to find people and to offer her flowers”.
	(Therapist: What or whom is she waiting?)	(No help from the therapist was used during execution).
	“I do not know...”	




Figure 8. Artistic picture used for the task

responses became longer and precise. The patient was able to answer with complete coherent sentences, which wasn't observed in initial assessment. The patient became able to fulfil tasks of writing and complete the answers to the open questions according to the content of thematic and artistic images. Such answers were completely absent during initial assessment. It is possible to notice positive progress with verbal and general intellectual initiative together with consolidation of visual and spatial orientation. The Table 4 resumes positive changes in assessment of the patient before and after rehabilitation.

4. DISCUSSION

Regarding aphasia syndrome, Luria [37] proposed clinic classification according to the central functional mechanism for each form of aphasia [38]. Such central mechanism might be

detected by qualitative clinic assessment and syndrome analysis [1]. In the case of dynamic aphasia, Tsvetkova [39] has stressed the affection of dynamic psychological programs for speech production or lack of creative internal schemes of expression. Reading and writing, as active productive process is also affected. Simple sensorial and motor acts are preserved in this syndrome, which includes simple perception, discrimination, articulation and coping. The central deficit is related to the lost of initiative for productive communication; in some cases, the patients present lack of motor and general activity [3]. The patients might show slow movements and slow face expressions [40,41, 17]. Precisely those were the difficulties presented by our patient during initial assessment. Understanding of oral speech was preserved, but the patient was unable to show any kind of productive forms of verbal and non-verbal communication.

Table 4. Main changes during fulfillment of the tasks of assessment

Neuropsychological assessment		
Tasks	Initial Assessment	Final Assessment
Drawings	Difficulties or absence of the shapes	Positive changes in representation of the shapes and elements of objects, recognizable drawings
Writing	Impossibility	Attempts of writing of letters and words with external marked lines
Oral production	Only by repetition	Proper sentences and attempts of narration
General attitude	Negative attitude to all tasks, especially to all kind of graphic tasks, whipping, poor initiative and communication	Acceptation of graphic tasks, good mood, positive relation with family and rehabilitation, participation in day-to-day activities at home

It is important to stress that there is no evidence reported cases of dynamic aphasia in left-handed Spanish speaking patients [27]. It is important to continue with the usage of Luria's conception of qualitative clinic analysis of cases with aphasia while working with the patients in different linguistic contexts.

In particular case of dynamic aphasia, the feature of the absence of verbal communicative initiative is an important clinic feature, which might be found during fulfilment of different verbal and non-verbal tasks in situations of communication between the patient and neuropsychologist. The authors express the necessity of presentation and publication of particular clinic cases to academic international community within qualitative clinic tradition of Luria's conception.

The main difference between dynamic aphasia and "frontal syndrome" were very expressive speech difficulties of the patients with dynamic aphasia. On the contrary, patients with "frontal syndrome" or patients with severe difficulties in programming and control, in Luria's terms, didn't show pronounced speech defects but defects with complex intellectual and logic tasks. It is important to mention that it is possible to discuss possible secondary affection of programming and control in patients with dynamic aphasia. Light difficulties with programming and control might be found in these patients as a consequence of frontal lesion.

Our patient presented difficulties in intellectual tasks (constructions and logic sequence) only if these tasks included spatial relations. The reason of the difficulties in intellectual tasks was difficulties with spatial orientation and not with programming and control. Our argument to defend this position is the fact that the patient could overcome her difficulties after proposed program of rehabilitation, which was directed to speech initiative and to reorganization of spatial orientation. According to the literature and our own clinical experience, such quick positive effects are rare in patients with the predominance of frontal syndrome [16,40].

In our opinion, according to Luria's approach, it is necessary to find unique central mechanism of difficulties of each patient and to make the decision about diagnosis. From this point of view, poor verbal initiative with adequate repetition should help for diagnosis of dynamic aphasia instead of "fontal syndrome" without aphasia. The progress of the patient during rehabilitation

permits to approve diagnosis of dynamic aphasia as a predominant syndrome of the patient together with the presence of strong spatial difficulties. Patients with predominant deficits of "executive functions" after frontal lesions normally don't show such positive results after rehabilitation [16].

One of the most remarkable facts of our study is that the patient was left-handed. As we have mentioned, there are no cases of patient with dynamic aphasia in Spanish speaking patients, neither data of successful rehabilitation. There is no mention of cases of patients of dynamic aphasia in left-handed patients at all. It is important to stress that after Broca works [41], the majority of researchers were convinced that right hemisphere is dominant for speech in left-handed patients. Later research has shown that predominantly left-handed subjects do not show an inverted representation of brain cognitive functions [42,43].

The majority of published reports have found that 96-99% of right-handed and only 60% of left handed have shown left dominance for verbal processes. The rest of left-handed patients may present right dominance or mixt dominance for speech processes [43,44,45,46,47]. This fact may help to understand why left-handed subjects might present aphasia syndromes after brain injury in left hemisphere. At the same time, their difficulties might be not so severe as in right-handed patients. The best prognosis for rehabilitation might be noticed in patients with mixture dominance for speech processes [44].

The incidence of aphasia in left-handed subjects after brain damage in the right hemisphere is approximately 30% [48]. In addition, it has been proposed that the spatial difficulties in cases of crossed aphasia might appear in 50% [49]. Some authors have reported the presence of the verbal problems in left-handed patients who suffered injury in right hemisphere [50,51,52]. These studies illustrate that motor speech functions in left-handed subjects might be related to the functions of right hemisphere.

The patient in our study has presented very particular clinic picture with both sever dynamic aphasia and severe disturbance of visual and spatial functions as a consequence of bilateral frontal brain injury in left-handed subject. In this particularly case, together with all clinic features of dynamic aphasia described by Luria, strong difficulties with all tasks of drawing and writing,

construction and spatial and visual recognition were detected during initial assessment. The errors with spatial rotation and inversion of perceptive images were typical errors in the majority of perceptual tasks. At the end of the process of rehabilitation, the patient managed to fulfill all the mentioned tasks correctly, as the errors of rotation and inversion have completely disappeared. The patient became able to accomplish orientation at home, in the street and in other situations and has become much more independent in her day-to-day life.

Regarding the process of elaboration and application of the program of rehabilitation, it is important to stress that initial execution and responses of the patient were very important. Qualitative analysis of errors and difficulties of the patient was the main source for organization of the tasks inside the applied program. For example, the absence of any kind of own initiative for oral expression and rejection of participation in verbal tasks, obliged to choose spatial constructive and drawing tasks in order to provide positive initiative. Later on, it was possible to pass to written language and reading. Only after this training, the possibility for active usage of oral speech was restored. The patient has noticed own advances and positive changes in activity. So, we might say that in specific cases of patients, the tasks for rehabilitation of oral speech might follow the work with constructive, drawing tasks and oral expressions in dialogs.

Individual approach is an important advantage of qualitative methods for assessment and rehabilitation with patients. Precise and detailed analysis of the kinds of patient's difficulties on different levels of actions (concrete, perceptive and verbal) helped to propose useful tasks, especially regarding spatial orientation. The work only with verbal initiative with exclusion of spatial tasks wouldn't be enough for positive rehabilitation of our patient.

The authors are convinced that proper selection of visual and constructive tasks during initial stages has permitted to guarantee recuperation of communicative initiative and optimization of the mood of the patient and her verbal productive activity [53]. Orientation and external help provided by the therapist was organized on specific cards, which included structure and steps for each task during the sessions of neuropsychological rehabilitation [54]. The active usage of orientation cards during fulfillment of the tasks was of great help and permitted positive

transition of planning, execution and control during the work. Such orientation cards were used regularly during initial stages of the program and became unnecessary during final steps, while the patient as become more and more independent. These considerations contrasts with some studies, in which the tasks are proposed for the production of sentences, without providing any type of help and only in situations of constant mechanic repetition [55]. Proposed program of rehabilitation was created on the basis of concepts of cultural activity [39,36,16,56,57,58], which takes into account motives and interests of the patients. Such methodology is mostly new in Mexico and other countries of Latin America.

We believe that qualitative neuropsychological assessment is the basis for the elaboration of the stages of rehabilitation [59,60]. In this particular case, the program considered the tasks for general activation and visual and spatial functions, which have permitted to achieve notable progress in both speech production and intellectual construction tasks. Activation of spatial tasks helped to activate general initiative for any kind of activity, which helped also for activation of the verbal initiative of the patient. Our results show the essential relation between verbal and non-verbal process [61] and the necessity of inclusion of a variety of tasks in cases of aphasia in adults with bilateral damage. According to the work with the program of rehabilitation, positive changes were achieved in expressive language, reading and written production. The patient became able to produce complex sentences according to proposed communication and solution of intellectual tasks. The oral speech of the patient showed the coherence and communicative initiative.

5. CONCLUSIONS

1. Left-handed patients with bilateral brain damage might present dynamic aphasia together with complex visuo-spatial difficulties.
2. It is possible to offer appropriate measures for general cognitive rehabilitation together with the overcoming of the difficulties with verbal initiative. The most severe symptoms of dynamic aphasia have disappeared as the result of the work with the program of rehabilitation.
3. Strait relation between qualitative procedures of neuropsychological assessment and rehabilitation are

essential for success while working with adults with brain injury. The data of qualitative assessment help to establish individual process of rehabilitation.

CONSENT

As per international standard or university standard, patient's consent has been collected and preserved by the authors.

ETHICAL APPROVAL

As per international standard or university standard ethical approval has been collected and preserved by the authors.

COMPETING INTERESTS

Authors have declared that no competing interests exist.

REFERENCES

1. Luria AR, Tsvetkova LS. Towards the mechanisms of dynamic aphasia. *Acta Neurol Psychiatr Belg*. 1967;67(11):1045-1057.
2. Luria AR. *Funciones Corticales Superiores*. Moscú. Universidad Estatal de Moscú; 1969.
3. Costello A, Warrington EK. Dynamic aphasia: The selective impairment of verbal planning. *Cortex*. 1989;25:103-114.
4. Lichtheim L. 1885 On aphasia. *Brain*. 1989; 4:463-484.
5. Kleist K. *Gehirnpathologie: Vornehmlich auf grund der kriegserfahrungen*. Leipzig, Germany: J.A. Barth; 1934.
6. Esmonde T, Giles E, Xuereb J, Hodges J. Progressive supranuclear palsy presenting with dynamic aphasia. *Journal of Neurology and Psychiatry*. 1996;60:403-410.
7. Robinson G, Shallice T, Cipolitti L. Dynamic aphasia in progressive supranuclear palsy: A deficit in generating a fluent sequence of novel thought. *Neuropsychologia*. 2006;44:1344-1360.
8. Daniele A, Barbier A, Di Giuda D, Vita MG, Piccininni Ch, Spinelli P, Tondo G, Fasano A, Colosimo C, Giordano A, Gainotti G. Selective impairment of action-verb naming and comprehension in progressive supranuclear palsy. *Cortex*. 2013;49:948-960.
9. Warren JD, Warren JE, Fox NC, Warrington EK. Nothing to say, something to sing: Primary progressive dynamic aphasia. *Neurocase*. 2003;9(2):140-155.
10. Robinson G. Primary progressive dynamic aphasia and parkinsonism: Generation, selection and sequencing deficits. *Neuropsychologia*. 2013;51: 2534-2547.
11. Goldstein K. *Language and language disturbances*. New York: Grune and Stratton; 1948.
12. Gold M, Nadeau SE, Jacobs DH, Adair JC, Gonzalez-Rothi LJ, Heilman KM. Adynamic aphasia: A transcortical motor aphasia with defective semantic strategy formation. *Brain and Language*. 1997;57: 374-393.
13. Mesulam MM. Aphasia, sudden and progressive. In: H. Whitaker (Ed.) *Concise encyclopaedia of brain and language*. New York, Elsevier. 2010;49-53.
14. Whitaker HA. Language disorders, aphasia. In: H. Whitaker (Ed.) *Concise encyclopaedia of brain and language*. New York, Elsevier. 2010;272-278.
15. Robinson G, Shallice T, Cipolitti L. A failure of high level verbal response selection in progressive dynamic aphasia. *Cognitive Neuropsychology*. 2005;22(6):661-694.
16. Tsvetkova L. *Cerebro e Intelecto*. Moscú: Educación; 1996.
17. Akhutina TV. *Análisis neuropsicológico de la afasia dinámica*. Moscú: Terevinf; 2002.
18. Gupta SR, Mlcoch AG, Scolaro C, Moritz T. Bromocriptine treatment of nonfluent aphasia. *Neurology*. 1995;45:2170-2173.
19. Ozeren A, Sarica Y, Mavi H, Demirkiran M. Bromocriptine is ineffective in the treatment of chronic nonfluent aphasia. *Acta Neurologica Belgica*. 1995;95:235-238.
20. Gold M, Van Dam D, Silliman ER. An open-label trial of bromocriptine in nonfluent aphasia: A qualitative analysis of word storage and retrieval. *Brain and Language*. 2000;74:141-156.
21. Gonzalez-Rothi LJ. Behavioral compensation in the case of treatment of acquired language disorders resulting from brain damage. In: Dixon RA, Bachman L (Eds.) *Compensating for psychological deficits and declines: Managing losses and promoting gains*. Mahwah, NJ, Erlbaum. 1995;219-230.
22. Helm-Estabrooks N, Holland AL. *Approaches to the treatment of aphasia*. San Diego, Singular Publishing; 1998.

23. Huntley RA, Rothi LJG. Treatment of verbal akinesia in a case of transcortical motor aphasia. *Aphasiology*. 1988;2(1): 55-65.
24. Schuell H. Aphasia theory and therapy: Selected lectures and papers of Hildred Schuell. Baltimore: University Park Press;1974.
25. Porch BE. Treatment of aphasia subsequent to the Porch Index of Communicative Ability (PICA). In: R. Chapey, (Ed.) *Language intervention strategies in adult aphasia*. Philadelphia: Lippincott. 2001;663-674.
26. Martin N, Dell GS. Perseverations and anticipations in aphasia: Primed intrusions from the past and future. *Seminars in Speech and Language*. 2004;25(4):349-362.
27. Morán G, Solovieva Yu, Quintanar L, Machinskaya R. Rehabilitación neuropsicológica en un caso de afasia dinámica en una paciente zurda. *Revista Neuropsicología Latinoamericana*. 2013;5 (1):1-13.
28. Bilbao BA, Jiménez CM, Palomar FM. *Guía para familias*. España: FEDACE; 2005.
29. Quintanar L, Solovieva Y. *Evaluación neuropsicológica breve para adulto*. México: Universidad Autónoma de Puebla; 2013.
30. Quintanar L, Solovieva Y, León-Carrión J. *Diagnóstico clínico de la afasia Puebla-Sevilla*. México: Universidad Autónoma de Puebla; 2011.
31. Quintanar L, Solovieva Yu. *Evaluación neuropsicológica en la edad escolar*. México, Universidad Autónoma de Puebla; 2012.
32. Zeigarnik BV. *Psicopatología*. Madrid: Akal; 1981.
33. Quintanar L, Solovieva Y. *Métodos de rehabilitación en la neuropsicología del adulto*. México: Universidad Autónoma de Puebla; 2001;
34. Luria AR. *Afasia traumática*. Moscú. Academia De Ciencias Médicas;1948.
35. Tsvetkova LS. *Enseñanza rehabilitatoria de pacientes con afasia*. Moscú. Universidad Estatal de Moscú;1985.
36. Tsvetkova L. *Afasia y enseñanza rehabilitatoria*. Moscú: Enseñanza;1988.
37. Luria AR. *El cerebro en acción*. Barcelona: Fontanella; 1978.
38. Quintanar L. *Modelos neuropsicológicos en afasiología*. Aspectos teóricos y metodológicos. México: BUAP; 1994.
39. Tsvetkova L. *Reeducación del lenguaje, la lectura y la escritura*. Barcelona: Fontanella; 1977.
40. Luria AR. *Bases de neurolingüística*. Moscú: Universidad Estatal de Moscú; 1975.
41. Broca P. Sur la faculté du language articule. *Bulletin Sociology and Anthropology*. 1865 ;6:337-393.
42. Goodglass H, Quadfasel FA. Language laterality in left-handed apha-sics. *Brain*. 1954;77(4):521-548.
43. Hécaen H, Y Sauguet J. Cerebral dominance in left-handed subjects. *Cortex*. 1977;17:19-48.
44. Damasio AR, Damasio H, Rizzo M. Aphasia with nonhemorrhagic lesions in the basal ganglia and internal capsule. *Archives of Neurology*. 1982;39(1):15-24.
45. Alexander MP, Hiltbrunner B, Fischer RS. Distributed anatomy of transcortical sensory aphasia. *Archives of Neurology*. 1989;46(8):885- 892.
46. Giorgis GM, Rohde CG, Bravo MM, Y Vielma PJ. *Afasia Cruzada*. *Revista Neurología Argentina*. 2001;26:123-25.
47. Glass A, Butler SR, Carter JC. Hemispheric asymmetry of EEG alpha activation: Effects of gender and familial handedness. *Biological Psychology*. 1984; 19(3):169-187.
48. Joannette Y. Aphasia in left-handers and crossed aphasia. In Boller F, Grafman J. (Eds.). *Handbook of neuropsychology*. Amsterdam, Elsevier. 1989;173-183.
49. Alexander MP, Annett M. Crossed aphasia and related anomalies of cerebral organization: Case reports and genetic hypothesis. *Brain and Language*. 1996;55: 213-239.
50. Van Strien JW, Y Bouma A. Cerebral organization of verbal and motor functions in left-handed and right-handed adults: Effects of concurrent verbal tasks on unimanual tapping performance. *Journal of Clinical and Experimental Neuropsychology*. 1988;10(2):139.
51. Tzourio N, Crivello F, Mellet E, Nkanga-Ngila B, Mazoyer B. Functional anatomy of dominance for speech comprehension in left handers vs right handers. *NeuroImage*.1998;8(1): 1-16.
52. Knecht S, Dräger B, Deppe M, Bobe L, Lohmann H, Flöel A, Ringelstein EB, Y Henningsen H. Handedness and hemispheric language dominance in

- healthy humans. Brain. 2000;123(12): 2512-2518.
53. Rodríguez F, Solovieva Y, Bonilla R, Pelayo H, Quintanar, L. Rehabilitación neuropsicológica en un caso de afasia semántica. Revista Neuropsicología Latinoamericana. 2011;3(2):39-49.
54. Talizina NF. La teoría de la actividad aplicada a la enseñanza. México: Universidad Autónoma de Puebla; 2009.
55. Bormann T, Wallesch CW, Blanken G. Verbal planning in a case of dynamic aphasia: An impairment at the level of macro planning. Neurocase. 2008;14(5): 431-450.
56. Talizina NF, Solovieva Yu, Quintanar L. Enseñanza de las matemáticas desde la teoría de la actividad. México: CEIDE; 2017.
57. Talizina N, Solovieva Yu, Y Quintanar L. La aproximación de la actividad en psicología y su relación con el enfoque histórico-cultural de L.S. Vigotsky. Novedades educativas. 2010;22:230:4-9.
58. Quintanar L, Solovieva Yu. Rehabilitación Neuropsicológica. Historia, Teoría y Práctica. México: Universidad Autónoma de Puebla; 2016.
59. Chastinet J, Morais C, Solovieva Y. Rehabilitación de un caso de afasia acústico-mnésica como resultado de un trauma craneoencefálico: Un abordaje Luriano. Revista Neuropsicología Latinoamericana. 2011; 3(1):27-39.
60. Solovieva Yu, Quintanar L. Intellectual activity in Patients with semantic and motor afferent aphasia. International Neuropsychiatric Disease Journal. 2017;9 (1):1-11.
61. Quintino-Aires J. Neurogenese da linguagem. São Paulo: IPAF Editora; 2010.

© 2018 Solovieva and Quintanar; This is an Open Access article distributed under the terms of the Creative Commons Attribution License (<http://creativecommons.org/licenses/by/4.0>), which permits unrestricted use, distribution, and reproduction in any medium, provided the original work is properly cited.

Peer-review history:

*The peer review history for this paper can be accessed here:
<http://www.sciencedomain.org/review-history/25855>*