



Evaluation and Comparison of Functional and Aesthetic Outcomes of McGregor and Stepped Lower Lip-Split Incisions for Extirpation of Primary Tumor in Cases of Squamous Cell Carcinoma of Oral Cavity (SCCOC)

Chetan Gupta ^{a*}, Nitin Bhola ^a, Anendd Jadhav ^a and Akhil Sharma ^a

^a *Department of Oral and Maxillofacial Surgery, Sharad Pawar Dental College, Datta Meghe Institute of Medical Sciences (D.U), Wardha, Maharashtra, India.*

Authors' contributions

This work was carried out in collaboration among all authors. All authors read and approved the final manuscript.

Article Information

DOI: 10.9734/JPRI/2021/v33i51B33509

Editor(s):

(1) Giuseppe Murdaca, University of Genoa, Italy.

Reviewers:

(1) Manjula GB, King Khalid University, Saudi Arabia.
(2) Cherry Bansal, Era Medical University, India.

Complete Peer review History, details of the editor(s), Reviewers and additional Reviewers are available here:
<https://www.sdiarticle5.com/review-history/74526>

Study Protocol

Received 11 August 2021
Accepted 22 October 2021
Published 24 November 2021

ABSTRACT

Background: Clear surgical margins are of utmost importance in surgical oncological procedures. Secondary consideration includes the functional and aesthetic outcomes of the patients after the procedure. The recognised surgical approach to the posteriorly located oral cavity and oropharyngeal tumors involves the splitting of the lower lip with or without mandibulectomy. In order to perk up postoperative function and aesthetics, quite a lot of modifications of the unique midline lower lip-splitting incision have been projected by various authors till date. A stepped ladder lower lip split incision (LLSI) helps in improved functional and aesthetic outcomes.

Objectives: The prime accent of the study is to compare the McGregor LLSI and the stepped LLSI with respect to functional and aesthetic outcomes in tumors ablation for SCCOC.

Methodology: The study population (n=22) is assigned randomly in two equal groups as a subject in the ratio of 1:1. Systemically healthy histologically diagnosed patients of SCCOC requiring LLSI

for the tumours ablation will be included. In Group A- McGregor LLSI will be performed and in Group B- a Stepped LLSI would performed. Post-operative assessment of functional and aesthetic outcomes will be done.

Expected Results: A stepped ladder LLSI used for tumours ablation will be effective in preserving post-operative lip movement, lip competency and cosmesis.

Conclusion: Utility of a Stepped ladder LLSI for accessibility and ablation of posterior oral and oropharyngeal tumors would be undoubtedly beneficial for improving post-operative functional and aesthetic outcomes and could be executed in routine oncologic surgery.

Keywords: Lower lip split incision; aesthetic incision; mandibulectomy; oral squamous cell carcinoma.

1. INTRODUCTION

The basic tenet of any oncologic surgery is extirpation of tumors with the safe surgical margins while, maintaining the function and cosmesis after the ablative surgical procedure. Majority of intraoral tumors may be managed by an intraoral approach. However, in cases of trismus or posteriorly located tumours frequently pose difficult access for which a wide exposure is required. A splitting of the lower or upper lip can ease to reach the tumours [1]

The lower lip-split incision (LLSI) has been far rampantly implemented in head and neck (H&F) surgical oncology to offer enhanced access not only to intra-oral, pharyngeal and parapharyngeal tumours but also to the cervical part of spinal column. In mid-19th century Dieffenbach, Roux, Bernard, Trotter, Burow introduced midline straight incision. This incision not only combined along with a mandibulotomy/ mandibulectomy, but also be extended to the submandibular or the neck region, which allows a neck dissection [2].

Such transfacial approaches involving mid line straight lip splits incision are accompanied with bothersome aesthetic and functional post-operative sequelae. This may include unsightly scar, vermilion notching, chin-pad contour loss, dwindled lip sensation, lip mobility and oral commissure incontinence.

In an attempt to improve postoperative function and aesthetics, several modifications of the novel LLSI have been proposed by various authors till date. In 1839, Roux designed a midline lower lip incision which lies in a relaxed skin tension line (RSTL) and minimises damage to the underlying muscles, vessels and nerves of the lower lip [3,4].

McGregor and McDonald revised the original LLSI to trail the outline of the labio-mental groove. This improves the scar contracture as

this incision hide in RSTL [5]. But such curvilinear incision design may cause scar puckering due to circumferential scar contracture [6]. Ramon et al. [7], introduced a stepped ladder incision technique which reduces vertical and circumferential scar contracture and preserve chin pad getting disfigured [7].

No attempt in the past has been made to compare McGregor incision with Stepped incision approach for oncologic tumours ablation. Hence, this study is pondered to compare the functional and aesthetic outcomes of McGregor LLSI versus stepped incision design with the hypothesis that stepped incision design would improve the functional and aesthetic outcomes.

1.1 Objectives

1. **To evaluate the McGregor incision** with respect to functional and esthetic outcomes in tumor ablation for SCCOC.
2. **To evaluate the Stepped incision** with respect to functional and esthetic outcomes in tumor ablation for SCCOC.
3. **To compare the McGregor and Stepped incision** with respect to functional and esthetic outcomes in tumor ablation for SCCOC.

2. METHODS

Study Design: Prospective, comparative study design.

Setting: "The 22 histopathologically proven cases of SCCOC, reporting to department of Oral and Maxillofacial Surgery, Sharad Pawar Dental College and Hospital, and Acharya Vinoba Bhave Rural Hospital, Sawangi (M) Wardha (Maharashtra), who would undergo surgical resection of the primary tumour under general anesthesia between September 2020 to May 2021 were screened for the recruitment. This study will be performed in accordance with the

Helsinki declaration and its later amendments or comparable ethical standards and approval by institutional ethical guidelines prescribed by central ethics committee on human research (CECHR) of Datta Meghe Institute of Medical Sciences, Deemed to be University (Ref. No. DMIMS(DU)/IEC/2020-21/48)".

Patients fulfilling the criteria given below will be recruited for the study.

Inclusion Criteria:

1. Histologically proven cases of Oral squamous cell carcinoma where lip split incision is required for tumor ablation.
2. Medically fit patients under general anaesthesia.

Exclusion Criteria:

1. Immunocompromised and medically unfit patients for surgery.
2. Pre-operative treatment such as surgery/ radiotherapy or chemotherapy.
3. Patient with history of surgery in anterior chin region/ pre-existing scar and keloidal tendency.
4. Patients in whom ablative defect will extend to involve the lower lip and anterior mandible.

2.1 Preoperative Screening and Evaluation

All the patients who will satisfy the above mentioned criteria will be recruited for the study and detailed case history, TNM staging (acc to AJCC 7th edition, 2009 UICC guidelines) along with Histopathological grading (Broder's grading) of the primary tumor were precisely documented in the record proforma (Annexure- I). Patients would then be subjected to CECT/MRI in Department of Radio-Diagnosis, AVBRH, Sawangi (Meghe). Routine Blood investigations were done and the patient was posted for surgery under general anaesthesia with due fulfilment of the pre-anaesthetic checkup.

3. METHODOLOGY

The study population [n = 22] will be divided equally into two groups (group A (N=11) and group B) in a ratio of 1:1 by Lottery method of randomization. The subjects will be blinded to the allocation group.

3.1 Surgical Protocol

- All the cases will be operated by a single senior surgeon having considerable experience in oral oncology.

3.2 Surgical Technique

The patients will be randomly allocated by lottery method between two groups.

- **Group A** - McGregor incision will be used as the control incision to follow the outline of the lip-chin contour.
- **Group B**- a stepped incision technique starting with midline vermilion incision, continues down to 2mm above the mento-labial fold, where it extends 1 cm and then it is brought around the chin in small steps through the depressor labiinferioris muscle about 2 cm lateral to the mentalis muscle finally reaching the inferior mandibular edge lateral to the mentalis muscle.

3.3 Data Sources/ Measurement

The following parameters will be assessed and documented:-

- The average Intraoperative time required for surgery from incision to closure. It will be measured in seconds using a stopwatch.
- Post-operative lip movement and lip competency will be evaluated with asking patient to clench his teeth and retract the lip [8].
- Scar by Stony Brook Scar Evaluation Scale after 1 week and 1 month postoperatively [9].
- Post-operative complications like partial necrosis, hypertrophic scar and keloid will be assessed by

Variables: Time, function of lip, scar evaluation, postoperative complications.

Bias: There is no bias present.

Study size: The study size is arrived at,

Using the formula:

$$n = \frac{Z\alpha/2^2 \times P \times (1-P)}{d^2}$$

$$n = \frac{(1.96)^2 \times 0.01 \times (1-0.01)}{(0.06)^2}$$

= 10.56

i.e. 11 patients needed in each group.

Where,

$Z_{\alpha/2}$ = is the level of significance at 5% at confidence interval= 1.96.

P= Prevalence of oral premalignant lesion = 1% i.e 0.01 [10]

d= desired error of margin= 6% i.e 0.06

Statistical Methods: "Statistical analysis will be done by using descriptive and inferential statistics using chi-square test, Student's paired and unpaired t test, software used in the analysis will be SPSS 24.0 version and Graph Pad Prism 7.0 version and $p < 0.05$ will be considered as level of significance."

3. RESULTS

3.1 Evaluation of Intra-Operative Time Required for Each Incision in Seconds

Incision time would be recorded from the beginning of incision till the time the final closure by an independent observer using digital clock in seconds.

3.2 Evaluation of Post-Operative Lip Movement and Lip Competency

The post-operative lip movement and lip competency will be assessed by Clinical functional assessment test [8]. This would be done by the same clinician by asking the patient to clench his mouth and ask to move/retract lip on 7th and 330th post-operative day. The results would be noted as, on rest, on effort and incompetent and respective scores would be 1,2,3. The lower score will indicate better function.

3.3 Evaluation of Post-Operative Scar

The post-operative scar evaluation will be done by Stony Brook Scar Evaluation scale (SBSES) [9]. The questionnaire will be explained to the clinician in detail requiring them to select one option which closely describes the status of the scar. The assessment and evaluation will be performed by the same clinician at the 7th and 30th post-operative day. The obtained scores will be tabulated and statistically evaluated to calculate the result. These scores would

represent individual value which further summed and would rate '0' as worst and '5' as best scar.

3.4 Evaluation of Post-Operative Complication

Partial necrosis, hematoma and seroma will be assessed as present or absent.

3.5 Descriptive Data

Descriptive statistics will be done with the help of frequency, percentage, mean and standard deviation.

3.6 Discussion

The disease free survival in H&F cancer patients is very crucial it can be improved by various multimodality treatment option upto certain extent [11,12]. Emphasis should also be given to the quality of life [13]. In the modern epoch, the incisions are planned with immense value which should provide adequate enhanced wide exposure to the field of interest, facilitate reconstructive procedures and thereby maximize oncologic, functional and esthetic outcomes. The pattern of incision be governed by the site of the tumor and these are designed based upon certain anatomical landmarks [14,15].

The most perplexing surgical aspects include trouble in gaining adequate access to lesions of severe trismus patients, lesions present posterior to oral cavity and oro-pharyngeal lesions [16]. Pertaining to adequate access and ample exposure to the tumor, preservation of important neurovascular structures in the vicinity of the incision site becomes an edge. Failing to which may lead to functional impairment and aesthetic disfigurement [17,18].

The literature search reveals that, various access procedures to the head and neck tumour have been discussed and various lip splitting incisions were studied till date. The modest straight line vertical lower lip split incision advocated long ago in past is simple and reliable but has aesthetic and functional drawbacks. There is often scar contracture and vermilion notching because of loss of normal round and smooth architecture of lip-chin apparatus after closure post-operatively (Bernard in 1853, and Burowin 1855).

Langenbeck in 1877, advocated laterally access to the oral cavity by starting the incision from the

corner of mouth vertically along the lower edge of mandible. This incision results in unacceptable functional deformity as it cuts fibers of masseter, buccinators muscle and facial motor nerve supply to the lower lip [19].

Konig, in 1922 introduced median split method of the lower lip where vertical incision starts 1.5 cm medial to the corner of mouth over the inferior mandibular border. Again this technique leaves undesirable scar, lip eversion and small groove formation [19].

McGregor and MacDonald in 1983 modified midline LLSI rendering to the anatomy of the lip-chin apparatus. The prescribed design of the incision is as it starts in the midline, stops in the hollow just above the chin prominence. Then it curls around the base of the chin eminence to reach the submental area which further continues to aid in neck dissection [5].

Hyter et al. [20] in 1996 modified the McGregor incision but it was not practised routinely. Rapidis in [6], compared Hayter et al modification of McGregor incision gave the best post-operative results as compared to the Robson and Roux incision whereas, McGregor incision yielded good functional and esthetic results. Shetty et al. [21] described functional and aesthetic outcomes in 30 patients undergoing surgery of the oral cavity tumor extirpation requiring lower lip split incision. The author compared Roux, Robson and McGregor incision and concluded that McGregor incision produced the best results over other two incisions.

However, in the McGregor incision the curved portion may result in circumferential skin contracture which further results in scar puckering. Moreover, the extension over the lower border may cut the mentalis muscle fibers [19].

Table 1. Clinical functional assessment of lip competence [8]

Assesment by clinician		Score
Lip competence	At rest	1
	On effort	2
	Incompetent	3
Range 1–3, lower score indicating better function		

Table 2. The stony brooke scar evaluation test [9]

	Scar category	Points
Width	> 2mm	0
	≤ 2mm	1
Height	Elevated/depressed in relation to surrounding skin	0
	Flat	1
color	Darker than surrounding skin	0
	Same color or lighter than surrounding skin	1
Hatch marks/suture marks	Present	0
	Absent	1
Overall appearance	Poor	0
	Good	1
Total score – sum of individual score [Ranges from 0 (worst) -5 (best)]		

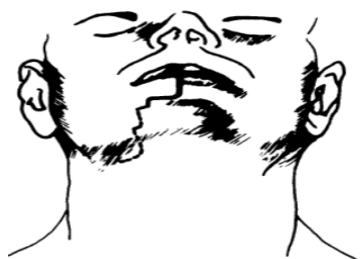

Fig. 1. Stepped incision

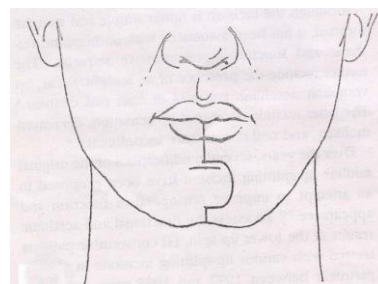


Fig. 2. McGregor incision

Ramon et al. [7], popularised stepped incision technique for surgical access splitting the lower lip. The design of this incision starts from the midline of the lower lip. A 2cm vertical incision is started from midline upto the labiomental fold then crosses 1 cm laterally on either side at 90 degree to the vertical limb. Further the incision is continued in small ladder like fashion besides the chin prominence. As the incision is divided through the depressor labii inferior muscle about 2 mm laterally to the mentalis muscle and reaches the lower anterior edge of the mandible lateral to the mentalis muscle, which allows best anatomic and functional reconstruction. The innervation of the lip muscle also not compromised. According to the author, this technique would improve the functional and esthetic outcomes and also suffice the improved access for the surgery.

No attempt in the past has been carried out to compare the stepped LLSI with the McGregor LLSI for functional and esthetic outcomes.

The major limitation of the present study is that it is attempted to compare only two LLSI for assessment in low power. If a stepped incision will be proven to be better in terms of improved post-operative function and reduced scar formation as the incision which is in the natural skin folds will provide quick, firm healing and excellent aesthetics and will be validate to use in routine oncologic access surgery.

4. CONCLUSION

The utility of a Stepped ladder LLSI for accessibility and ablation of posterior oral cavity and oropharyngeal tumors would be undoubtedly beneficial for improving post-operative functional and aesthetic outcomes and could be executed in routine oncologic surgery.

CONSENT

It is not applicable.

ETHICAL APPROVAL

It is not applicable.

COMPETING INTERESTS

Authors have declared that no competing interests exist.

REFERENCES

1. Tashiro H. Cosmetic improvement of the lateral mentolabial incision; 1982.
2. Gooris PJJ, Worthington P, Evans JR. Mandibulotomy: A surgical approach to oral and pharyngeal lesions. *Int J Oral Maxillofac Surg.* 1989;18(6):359–64.
3. Bhatt V, Praveen P, Green J, Grime PD. A Modified Lip Split Incision. *J Oral Maxillofac Surg.* 2009;67(1):229–30.
4. Robson MC. An easy access incision for the removal of some intraoral malignant tumors. *Plast Reconstr Surg.* 1979;64(6):834–5.
5. McGregor IA, MacDonald DG. Mandibular osteotomy in the surgical approach to the oral cavity. *Head Neck Surg.* 1983;5(5):457–62.
6. Rapidis AD, Valsamis S, Anterriotis DA, Skouteris CA. Functional and aesthetic results of various lip-splitting incisions: A clinical analysis of 60 cases. *J Oral Maxillofac Surg.* 2001;59(11):1292–6.
7. Ramon Y, Hendler S, Oberman M. A stepped technique for splitting of the lower lip. *J Oral Maxillofac Surg.* 1984;42(10):689–91.
8. Devine JC, Rogers SN, McNally D, Brown JS, Vaughan ED. A comparison of aesthetic, functional and patient subjective outcomes following lip-split mandibulotomy and mandibular lingual releasing access procedures. *Int J Oral Maxillofac Surg.* 2001 Jun;30(3):199–204.
9. Singer AJ, Arora B, Dagum A, Valentine S, Hollander JE. Development and validation of a novel scar evaluation scale. *Plast Reconstr Surg.* 2007;120(7):1892–7.
10. Singh MP, Kumar V, Agarwal A, Kumar R, Bhatt MLB, Misra S. Clinico-epidemiological study of oral squamous cell carcinoma: A tertiary care centre study in North India. *J Oral Biol Craniofacial Res.* 2016;6(1):32–5.
11. Gupta C, Bhola N, Jadhav A, Mishra A, Hingnikar P, Ghavat C. Does diagnostic accuracy of surgeon's perception outweigh frozen section analysis in determining intraoperative clear mucosal surgical margins in oral squamous cell carcinoma patients? *Natl J Maxillofac Surg.* 2020;11(2):182.
12. Agarwal A, Bhola N, Kambala R, Borle RM. Touch imprint cytology: can it serve as an alternative to frozen section in intraoperative assessment of cervical

- metastasis in oral squamous cell carcinoma? *J Oral Maxillofac Surg.* 2019;77(5):994–9.
13. Spiro RH, Gerold FP, Strong EW. Mandibular “swing” approach for oral and oropharyngeal tumors. *Head Neck Surg.* 1981;3(5):371–8.
 14. Patnaik VVG, Singla RK, Bala S. Surgical incisions-their anatomical basis: Part 1-head and neck. *J Anat Soc India.* 2000;49(1):69–77.
 15. Borle RM, Jadhav A, Bhola N, Hingnikar P, Gaikwad P. Borle’s triangle: A reliable anatomical landmark for ease of identification of facial nerve trunk during parotidectomy. *J Oral Biol Craniofacial Res.* 2019;9(1):33–6.
 16. Gupta A, Bhola N, Kambala R. Defect reconstruction in oral squamous cell carcinoma patient using novel patient-specific polyether ether ketone implant: Report of a case. *J Datta Meghe Inst Med Sci Univ.* 2021;16(1):212.
 17. Bhagat N, Jain H, Dandagi S, Verma A. Modified Lip Split Incision To Approach The Posterolateral Tongue: A Case Report. *Int J Contemp Med Res.*
 18. Ghavat C, Bhola N, Jadhav A, Deshpande N, Gupta C. Malignant Transformation of Solitary Cylindroma Involving the Frontonasal Region-A Rarity. *J Clin Diagn Res.* 2020;14(4).
 19. Rassekh CH, Janecka IP, Calhoun KH. Lower lip splitting incisions: Anatomic considerations. *The Laryngoscope.* 1995;105(8):880–3.
 20. Hayter JP, Vaughan ED, Brown JS. Aesthetic lip splits. *Br J Oral Maxillofac Surg.* 1996;34(5):432–5.
 21. Shetty AD, Prasad BR, Sebastian P. Clinical analysis of lip splitting incisions. *Int J Oral Maxillofac Surg.* 2007;36(11):982.

ANNEXURES

PROFORMA

Name- IPD No:
 Age/Sex- Date of admission-
 Address-
 Tel no-
 Diagnosis-
 Date of surgery-
 Treatment done-
 Incision type-

1. Time taken from incision to exposure surgical site:

2. Lip competency:

Assessment by clinician	Score	At 7 th post-op day	At 30 th post-op day
Lip competence	At rest	1	
	On effort	2	
	Incompetent	3	

Range 1–3, lower score indicating better function

3. Scar:

Stony Brook Scar Evaluation Scale [9]

	Scar category	Points	POD 7th	POD 30th
Width	> 2mm	0		
	≤ 2mm	1		
Height	Elevated/depressed in relation to surrounding skin	0		
	Flat	1		
color	Darker than surrounding skin	0		
	Same color or lighter than surrounding skin	1		
Hatch marks/suture marks	Present	0		
	Absent	1		
Overall appearance	Poor	0		
	Good	1		

Total score – sum of individual score [Ranges from 0 (worst) -5 (best)]

4. Post operative complection:

- a. **Partial necrosis:** present/absent
- b. **hematoma:** present/absent
- c. **seroma:** present/absent

© 2021 Gupta et al.; This is an Open Access article distributed under the terms of the Creative Commons Attribution License (<http://creativecommons.org/licenses/by/4.0>), which permits unrestricted use, distribution, and reproduction in any medium, provided the original work is properly cited.

Peer-review history:
 The peer review history for this paper can be accessed here:
<https://www.sdiarticle5.com/review-history/74526>