



# Pathomorphological and Immunohistochemical Study of Fibrosarcoma in an Adult Dog: A Case Report

Paras Saini <sup>a\*</sup>, Babu Lal Jangir <sup>a</sup>, Gulshan Narang <sup>a</sup>,  
Rakshita Sharma <sup>a</sup> and Priyanka <sup>b</sup>

<sup>a</sup> Department of Veterinary Pathology, College of Veterinary Sciences, Lala Lajpat Rai University of Veterinary and Animal Sciences, Hisar, Haryana, India.

<sup>b</sup> Department of Veterinary Surgery and Radiology, College of Veterinary Sciences, Lala Lajpat Rai University of Veterinary and Animal Sciences, Hisar, Haryana, India.

## Authors' contributions

This work was carried out in collaboration among all authors. All authors read and approved the final manuscript.

## Article Information

DOI: <https://doi.org/10.9734/acri/2024/v24i5755>

## Open Peer Review History:

This journal follows the Advanced Open Peer Review policy. Identity of the Reviewers, Editor(s) and additional Reviewers, peer review comments, different versions of the manuscript, comments of the editors, etc are available here: <https://www.sdiarticle5.com/review-history/119230>

Case Report

Received: 25/04/2024  
Accepted: 28/06/2024  
Published: 02/07/2024

## ABSTRACT

**Aim:** The objective of the present case report is to describe pathomorphological findings and immunohistochemical expression of pancytokeratin (PCK), vimentin, proliferating cell nuclear antigen (PCNA) and Ki67 in a case of fibrosarcoma in dog.

**Case Presentation:** A large, round ball-like growth of approximately 14 centimetres in diameter was noticed on caudal aspect of left thigh region in ten years old male bull dog. Its surface was

\*Corresponding author: Email: [sainiparas700@gmail.com](mailto:sainiparas700@gmail.com);

ulcerated. It was soft in consistency and cut surface appeared pinkish-white. Giemsa-stained smears revealed spindle cells with elongated nuclei containing granular chromatin, single to multiple nucleoli and scanty cytoplasm. Histopathological examination revealed moderately to well-differentiated neoplastic fibroblasts arranged in interwoven pattern with the presence of collagenous stroma. Neoplastic cells were characterized by pleomorphic, oval to elongated nuclei with single to multiple prominent nucleoli and moderate to scanty cytoplasm. Mitotic count was 1.2/high power field. The Immunohistochemical staining revealed intracytoplasmic positive immunoreactivity for vimentin and no immunoreactivity for PCK. Proliferating neoplastic cells revealed mild to strong nuclear immunostaining for PCNA and Ki67 with 56.7% PCNA index and 4.0% Ki67 index.

**Conclusion:** Based on histopathological findings, the case was diagnosed as fibrosarcoma. Immunopositive reactivity for vimentin and no immunoreactivity for PCK indicated the mesenchymal origin of the tumour. Histopathological features, low mitotic count and low Ki67 index suggested the less aggressive behaviour of the tumour in the present case.

*Keywords: Dog; fibrosarcoma; immunohistochemical expression; pathomorphological findings.*

## 1. INTRODUCTION

In the recent years, due to widespread use of vaccines and antibiotics in dogs, the deaths as a result of infectious diseases have been reduced to a greater extent. However, cancer is becoming a leading cause of death in dogs, which accounts for approximately 27% mortalities [1]. Fibrosarcoma is a slow-growing malignant neoplasm of the fibrocytes and is mostly seen in adult dogs. Fibrosarcoma can occur anywhere on the body however, head and limbs are mostly involved. Golden retrievers and Doberman pinchers are the dog breeds those are at high risk of developing fibrosarcoma [2]. Fibrosarcoma account for as much as 7.6% of all skin tumours in dogs [3] and is third most common malignant tumour found in the oral cavity of dogs [4]. For the diagnosis of tumours, histopathological examination is considered as gold standard technique. However, in undifferentiated tumours and the metastases in distant organs, histopathology is not sufficient for the confirmatory diagnosis. For such cases, immunohistochemistry using specific markers is useful for confirmatory diagnosis. Besides, the confirmatory diagnosis, aggressiveness of tumour is also assessed by studying the expression of the proliferating tumour markers by immunohistochemistry [5]. Keeping above facts in view, present study was undertaken to study cytological, gross and histopathological features and immunohistochemical expression of pancytokeratin (PCK), vimentin, proliferating cell nuclear antigen (PCNA) and Ki67 in fibrosarcoma in ten years old male bull dog.

## 2. CASE PRESENTATION

Ten years old male bull dog was presented to the Department of Veterinary Clinical Complex at the College of Veterinary Sciences (COVS), Lala Lajpat Rai University of Veterinary and Animal Sciences (LUVAS), Hisar with history of a large round ball-like growth of approximately 14 cms in diameter on the caudal aspect of the left thigh region. Tumour mass was surgically excised and impression smears were taken on the dry, clean, and grease-free glass slides. After drying, smear was fixed with absolute methanol. The impression smears fixed with methanol were immersed in a staining solution consisting of 1 part Giemsa stain (HiMedia) and 4 parts double distilled water (DDW) for 30 minutes and subsequently washed under tap water and dried properly.

### 2.1 Histopathology and Immunohistochemistry

The representative tissue sample was collected and fixed in 10% neutral buffered formalin for histopathological and immunohistochemical examination.

#### 2.1.1 Histopathology

After fixation, tissue samples were processed routinely by paraffin embedding technique by standard protocol [6]. Formalin fixed tissue sample of approximately 2-3 mm thickness was washed overnight under tap water to remove excess of formalin. Then, dehydrated in ascending grades of ethanol (50, 70, 90, 100%) for one hour each and cleared in benzene (2 changes of 30 minutes each). Thereafter, tissue

was placed in molten paraffin (3 changes of 45 minutes each) and finally embedding was done in paraffin. The tissue sections of 5 µm thickness were cut by using Histocore Multicut Leica Microtome System and stained with haematoxylin and eosin (H&E) stain and Masson's trichrome stain [6]. In tissue sections stained with Masson's trichrome, cell nuclei appear black; cytoplasm, keratin, muscle fibers, and intercellular fibers are red; and collagen is blue [6].

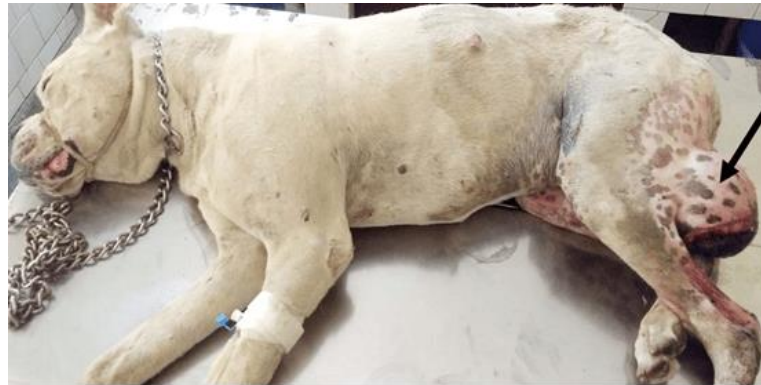### 2.1.2 Immunohistochemistry

The immunohistochemical expression of PCK, vimentin, PCNA and Ki67 was studied. For immunohistochemistry (IHC), sections were taken on 3-Amino propyl-triethoxysilane coated slides. The IHC was performed as per the standard procedure [7] with minor modifications. Briefly, the sections were deparaffinized with 2 changes of xylene and rehydrated with descending grades of alcohol and brought to distilled water. Antigen retrieval was carried out by subjecting the sections, immersed in citrate buffer (pH-6.0), to microwave irradiation at 800 Watts for 30 min. (20 cycles of 90 sec each). Blocking of endogenous peroxidase activity was carried out by immersing the sections in 3% hydrogen peroxide solution in absolute methanol for 45 min. The sections were covered with primary antibodies viz. Anti-pancytokeratin mouse monoclonal (PCK-26) (Sigma Aldrich), anti-vimentin antibody mouse monoclonal (V9) (Sigma Aldrich), anti-PCNA antibody mouse monoclonal (PC 10) (Sigma Aldrich) and anti-Ki67 antibody rabbit monoclonal (SP6) (Thermo Fisher Scientific Invitrogen) at 1:200, 1:400, 1:400 and 1:25 dilutions, respectively, and incubated overnight at 4 °C. Thereafter the sections were covered with secondary antibody (anti-mouse antibody for PCK, vimentin and PCNA, and anti-rabbit for Ki67) and Extravidin peroxidase (1:20 dilution; Sigma Aldrich) and incubated for 45 min. The sections were washed, after every step starting after antigen retrieval till colour development, thrice with PBS (pH = 7.2-7.4) for 5 min. each by continuous slow stirring on shaker. Colour development was carried out by covering the sections with 3-Amino-9-ethyl-carbazole (AEC; Sigma Chemicals, USA) prepared as per the manufacturer's instructions. Sections were then counterstained with Gill's haematoxylin (Sigma Aldrich). For negative

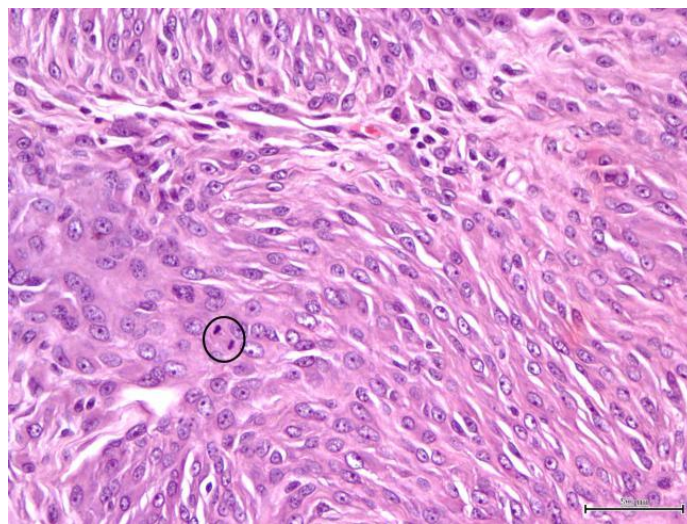
control the duplicate section was incubated with 1% bovine serum albumin excluding the primary antibodies and rest of the procedure was same. For PCK and vimentin, brick red to brown coloured cytoplasmic staining, however, for PCNA and Ki67 brick red to brown coloured nuclear staining in neoplastic cells was considered positive. PCNA and Ki67 indices were calculated by counting a minimum of 1000 neoplastic cells across 7-10 high-power fields (40× objective lens). These indices were expressed as percentages by determining the proportion of immunopositive neoplastic cells relative to the total number of neoplastic cells counted.

### 2.2 Pathomorphological and Immunohistochemical Findings

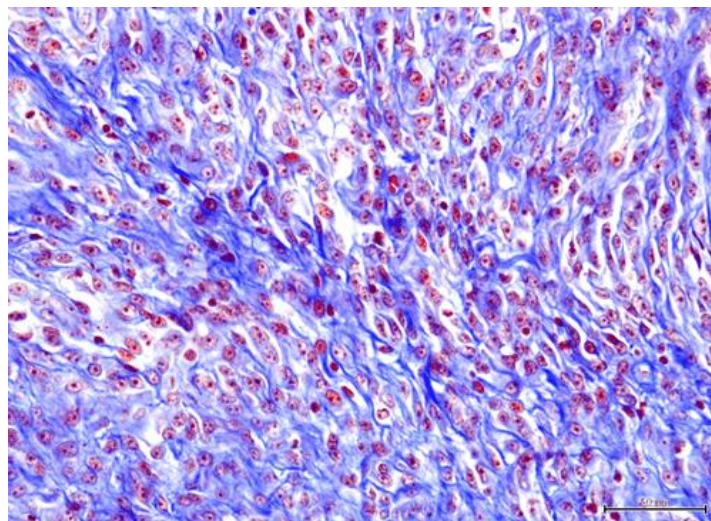
The tumour mass was observed on the caudal aspect of the left thigh region. It appeared round ball-like growth with approximately 14 cms in diameter (Fig. 1). Tumour mass was soft in consistency and cut surface appeared pinkish-white in colour. Cytological examination of Giemsa-stained smears revealed the individual spindle cells characterized by the presence of elongated nuclei with granular chromatin, single to multiple prominent nucleoli and scanty cytoplasm forming bipolar tail-like structures. Based on cytological examination, the present case was diagnosed as malignant spindle cell tumour. On histopathological examination, it revealed spindle to elongated neoplastic cells arranged in the interwoven pattern. Neoplastic fibroblasts were characterized by presence of pleomorphic, oval to elongated nuclei with single to multiple prominent nucleoli and scanty to moderate cytoplasm (Fig. 2) and collagenous stroma was also evident. Mitotic figures were infrequent with mitotic count of 1.2/high power field (40× objective). Masson's trichrome staining revealed moderate amount of blue coloured collagen fibres (Fig. 3). IHC revealed brick red to brown coloured intracytoplasmic immunopositive reaction for vimentin (Fig. 4) and no immunoreactivity for PCK in neoplastic cells. The neoplastic cells revealed mild to strong nuclear brick red coloured immunopositive reaction for PCNA (56.7%) (Fig. 5), however, only few cells (4.8%) revealed mild to moderate nuclear immunoreactivity for Ki67 (Fig. 6).



**Fig. 1. A dome shaped growth on caudal aspect of left thigh in an adult bull dog (arrow)**

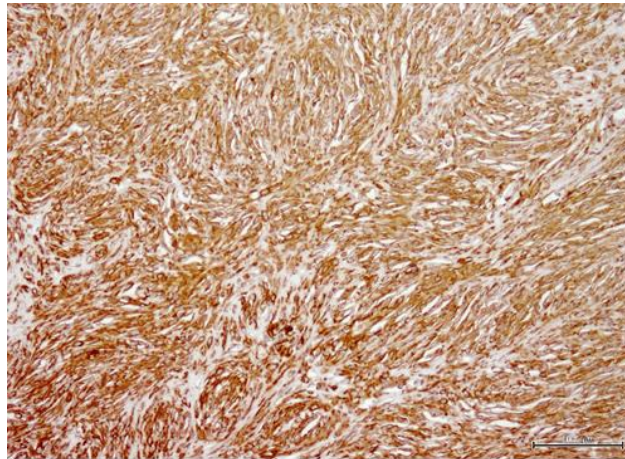


**Fig. 2. Fibrosarcoma: Spindle to elongated neoplastic cells arranged in interwoven pattern, characterized by pleomorphic, oval to elongated nuclei with single to multiple prominent nucleoli, scanty to moderate cytoplasm and presence of mitotic figure (encircled). H&E×400**

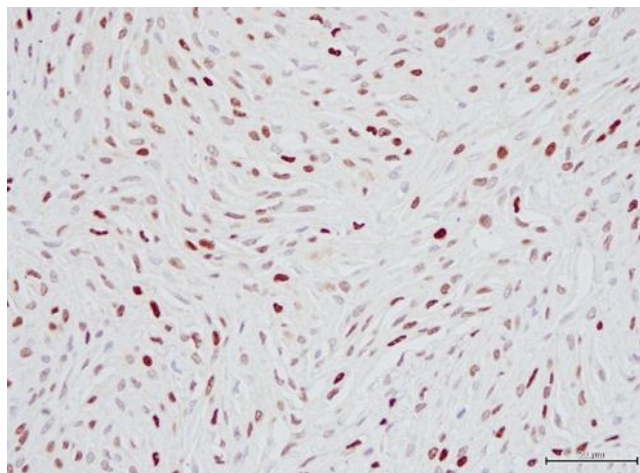


**Fig. 3. Fibrosarcoma: Moderate amount of blue coloured collagen fibres. Masson's trichrome ×400**

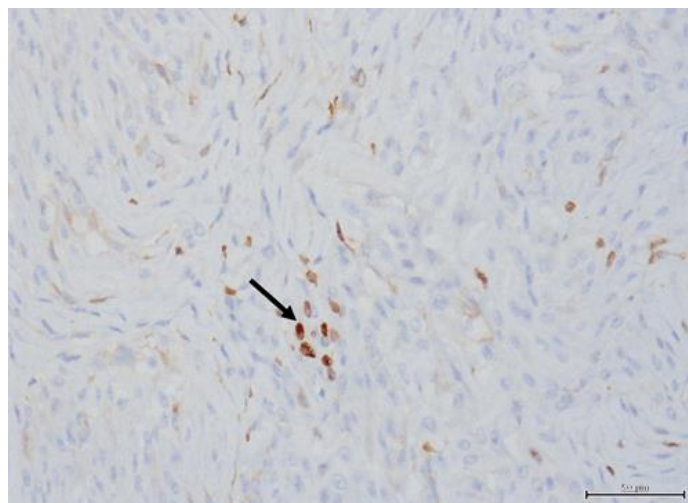




**Fig. 4. Fibrosarcoma: Brick red to brown coloured intracytoplasmic immunostaining for vimentin in neoplastic cells. IHCx200**



**Fig. 5. Fibrosarcoma: Mild to strong nuclear brick red coloured immunoreactivity for proliferating cell nuclear antigen in neoplastic cells. IHCx400**



**Fig. 6. Fibrosarcoma: Few neoplastic cells showing mild to moderate brick red to brown coloured nuclear immunoreactivity for Ki67 (arrow). IHCx400**

### 3. DISCUSSION

Fibrosarcoma has variable presentations depending on species and age of the animal, site of occurrence and etiopathogenesis. In the present study, fibrosarcoma was seen in ten years old male bull dog. This is in corroboration with Hendrick [2] who described that fibrosarcoma cases are mostly in adult dogs with mean age of 9 years. Similar to present study, Subapriya et al. [8] also observed a large round ball-like growth on the hind limb of dog which was confirmed as fibrosarcoma. The earlier studies revealed the fibrosarcoma cases in dogs at different sites [9,10,11]. However, contrary to present study, this case was reported in a young dog of one year age. More or less similar cytological and histopathological features were also reported by the earlier authors [8]. Masson's trichrome staining revealed the presence of blue coloured collagen fibres [12] which helped in differentiating it from the leiomyosarcoma.

Immunohistochemistry plays an important role in ascertaining the origin of neoplastic cells by use of diagnostic tumour markers and proliferation activity by studying the expression of proliferative markers. The cytokeratins form a group of different polypeptides which are expressed in the epithelial cells. Vimentin is the major component of the cytoskeleton in mesenchymal cells. This intermediate filament protein is found specifically in the cytoplasm of these cells and is mainly used to differentiate between epithelial and mesenchymal tumors [13]. The positive immunoreactivity for vimentin and no immunoreactivity for PCK indicated the mesenchymal origin of fibrosarcoma. Similar findings were also reported by the earlier workers in fibrosarcoma cases [14] who also reported vimentin immunoreactivity in fibrosarcoma in dog. In the present case, the PCNA index was high (56.7%), however, Ki67 index was very low (4.8%). This is possibly due to fact that PCNA is expressed maximum in S phase of the cell-cycle, but also detected in other phases of the cell-cycle and in non-cycling cells. It has a half-life of 8–20 hours [5]. However, Ki67 is expressed in all phases of cell-cycle with maximal expression in M phase and absent in non-cycling cells. Its half life is less than 1 hour [15].

### 4. CONCLUSION

In conclusion, present case was diagnosed as fibrosarcoma by histopathological examination.

The mesenchymal origin of neoplastic cells was confirmed by immunohistochemical expression of the vimentin. The proliferation activity of neoplastic cells was assessed by expression of PCNA and Ki67 by immunohistochemistry. Besides, histopathology, immunohistochemical expression of above tumour markers helped in describing the specific features of neoplastic cells.

### DISCLAIMER (ARTIFICIAL INTELLIGENCE)

Author(s) hereby declares that NO generative AI technologies such as Large Language Models (ChatGPT, COPILOT, etc) and text-to-image generators have been used during writing or editing of manuscripts.

### ETHICAL APPROVAL

The permission was obtained from Institutional Animal Ethics Committee, LUVAS (VCC/ IAEC/ 560-82, Dated: 18.03.2021).

### ACKNOWLEDGEMENTS

Authors are thankful to Head, Department of Veterinary Clinical Complex, LUVAS, Hisar for providing the tissue sample. Authors are also thankful to Head, Department of Veterinary Pathology, for providing necessary facilities for carrying out the investigation.

### COMPETING INTERESTS

Authors have declared that no competing interests exist.

### REFERENCES

1. Dhein ES, Heikkila U, Oevermann A, Blatter S, Meier D, Hartnack S et al. Incidence rates of the most common canine tumors based on data from the Swiss Canine Cancer Registry (2008 to 2020). *Plos One*. 2024;19(4):e0302231.
2. Hendrick MJ. Mesenchymal tumors of the skin and soft tissues. In: Meuten DJ, editor. *Tumors in Domestic Animals*. 5th ed. Ames, Iowa John Wiley and Sons, Inc; 2017.
3. Dobrin AA, Militaru M. Cytopathology and histopathology in diagnosis of malignant cutaneous and subcutaneous mesenchymal neoplasms in dogs-A review. *Lucrari Stiintifice Medicina Veterinara*. 2023;56(1):71-88.

4. Amishi, Verma Y, Swamy M, Jawre S, Dubey A, Rajput N. Oral fibrosarcoma in dog: Cytological, histopathological and immunohistochemical diagnosis. *Indian J Anim Res.* 2024;58(3):422-28.
5. Meuten DJ, editor. *Tumors in Domestic Animals.* 5th ed. Ames, Iowa John Wiley and Sons Inc; 2017.
6. Luna LG, editor. *Manual of Histologic Staining Methods of the Armed Forces Institute of Pathology.* 3rd ed. McGraw Hill Book Co. New York; 1968.
7. Ramos-Vara JA. Technical aspects of immunohistochemistry. *Vet Pathol.* 2005; 42(4):405-26.
8. Subapriya S, Vairamuthu S, Pazhanivel N, George RS, Vijayarani K, Gokulakrishnan M. Histopathological and immunohistochemical diagnosis of canine fibrosarcoma. *Int. J. Curr. Microbiol.* 2018; 7(6):1376-79.
9. Avci H, Yaygingul R, Gultekin M, Epikmen ET, Ural K, Belge A et al. Primary intestinal fibrosarcoma caused by intestinal perforation in a dog: A case report. *Vet Med (Praha).* 2012;57(6):314–19.
10. Dadhich A, Mathur M, Agrawal M, Palecha S, Arora AS. Pathological findings of fibrosarcoma in dogs. *Veterinary Practitioner.* 2019;20(2):184-85.
11. Soujanya S, Madhuri D. Cutaneous fibrosarcoma in a dog. *J Entomol Zool Stud.* 2019;7(1):861-63.
12. Ribeiro FTL, Assef MLM, Cirio SM. Histopathologic study of cutaneous fibrosarcoma in dogs (*Canis familiares*, Linnaeus, 1758) with different staining techniques. *Rev. Acad. Cienc. Anim.* 2009; 7(3):341-47.
13. Ramos-Vara JA, Borst LB. Immunohistochemistry: fundamentals and applications in oncology. In: Meuten DJ, editor. *Tumors in domestic animals.* 5th ed. John Wiley and Sons, Inc; 2017.
14. Vascellari M, Melchiotti E, Mutinelli F. Fibrosarcoma with typical features of postinjection sarcoma at site of microchip implant in a dog: histologic and immunohistochemical study. *Vet Pathol.* 2006;43(4):545-48.
15. Klopffleisch R, von Euler H, Sarli G, Pinho SS, Gartner F, Gruber AD. Molecular carcinogenesis of canine mammary tumors: New from an old disease. *Vet Pathol.* 2011;48(1):98–116.

**Disclaimer/Publisher's Note:** The statements, opinions and data contained in all publications are solely those of the individual author(s) and contributor(s) and not of the publisher and/or the editor(s). This publisher and/or the editor(s) disclaim responsibility for any injury to people or property resulting from any ideas, methods, instructions or products referred to in the content.

---

© Copyright (2024): Author(s). The licensee is the journal publisher. This is an Open Access article distributed under the terms of the Creative Commons Attribution License (<http://creativecommons.org/licenses/by/4.0>), which permits unrestricted use, distribution, and reproduction in any medium, provided the original work is properly cited.

Peer-review history:

The peer review history for this paper can be accessed here:  
<https://www.sdiarticle5.com/review-history/119230>