



A Case of Retroperitoneal Abscess: Complicated Appendicular Perforation

Abhik Dey ^{a+++*} and Ranjit Chowlek Shyam ^{b#}

^a Silchar Medical College and Hospital, Assam, India.

^b Nagaon Medical College and Hospital, Assam, India.

Authors' contributions

This work was carried out in collaboration between both authors. Both authors read and approved the final manuscript.

Article Information

Open Peer Review History:

This journal follows the Advanced Open Peer Review policy. Identity of the Reviewers, Editor(s) and additional Reviewers, peer review comments, different versions of the manuscript, comments of the editors, etc are available here: <https://www.sdiarticle5.com/review-history/109889>

Case Study

Received: 28/09/2023

Accepted: 05/12/2023

Published: 23/12/2023

ABSTRACT

A 23-year-old female presented to the emergency department of Silchar medical College and Hospital on 05-04-2022 with history of severe pain abdomen and vomiting for 3 days and passage of loose stool for 1 day with 3 months amenorrhea. On examination, tenderness, guarding elicited over right lumbar region. Ultrasound examination showed debrigenous collection in the RIF region and pouch of Douglas. Pain did not decrease even after administration of analgesics. CECT Abdomen showed appendicular perforation with retroperitoneal fasciitis. Exploratory laparotomy done with appendicectomy with abscess drainage. Post-operatively, patient had surgical site infection which resolved. The patient was discharged after 4 weeks after full recovery.

Keywords: Retroperitoneal abscess; Acute appendicitis; appendicular perforation.

1. INTRODUCTION

“Acute appendicitis is commonly encountered in daily practice, and with timely intervention

mortality and morbidity can be reduced. However, atypical presentation of acute appendicitis can lead to delay in diagnosis and treatment leading to increased mortality” [1].

⁺⁺ Senior Resident;

[#] Associate Professor of Surgery;

^{*}Corresponding author: E-mail: abhikdey437@gmail.com;

Few of the complications include appendicular lump formation leading to bowel obstruction, appendicular perforation with diffuse peritonitis and even retroperitoneal abscess. Retroperitoneal abscess [2] is recognized as a life-threatening condition because of its insidious clinical manifestations and diagnostic difficulty. The retroperitoneal abscess has the potential to spread rapidly to the perinephric space, via congenital anatomical communications to the psoas muscle, the lateral abdominal wall, and the lower extremities. "We, hereby, report a case of retroperitoneal abscess following appendicular perforation in a 23-year-old female" [3].

2. CASE REPORT

A 23-year-old female presented to the emergency department of Silchar Medical College and Hospital with complaints of severe pain abdomen and vomiting for 3 days and passage of loose stool for 1 day. The patient also had amenorrhoea for the past 3 months; pregnancy was ruled out by beta-hcg test. The pain was out of proportion. On examination, the patient had tachycardia, abdomen was found tender over the right lumbar region with guarding. A provisional diagnosis of (?) ovarian torsion was made.

On admission, the patient was started on Injectable analgesics, IV antibiotics, IV fluid and kept nil per oral. Abdominal ultrasound revealed debrigenous collection in the RIF region and minimal pouch of douglas fluid collection. Blood

investigations revealed total count- 13620 cells/cu mm, Hb- 11.7 g/dl, platelet count- 1.7 lakhs/cu mm. Chest Xray including abdominal xray showed normal study. CECT Abdomen showed appendicular perforation with retroperitoneal fasciitis.

The patient was put up for OT and emergency exploratory laparotomy done. Upon opening the peritoneum, moderate amount of pus aspirated out and caecum, terminal ileum, mesentery found adhered at the right iliac fossa. Pus source was located at the retroperitoneum around the peri-nephric area with perforated tip of gangrenous appendix with presence of 3 fecoliths. Appendix was removed and peritoneal and retroperitoneal toileting done. Drains placed at the retroperitoneum, right and left lumbar region. Abdomen closed back in layers. Pus sent for culture and sensitivity, and antibiotics modified as per sensitivity report.

Post-operatively, the patient suffered from surgical site infection and dyselektrolytemia. Gradually, the condition of the patient improved and orally allowed from 4th post-operative day. Abdominal drain output gradually decreased and removed on 6th post-operative day. The patient had wound dehiscence and regular wound dressing done with EUSOL. Secondary wound suturing done on postop day 19 and discharged on postop day 24. The patient was reviewed for stitch removal after 10 days. On subsequent followup, the patient was doing fine.

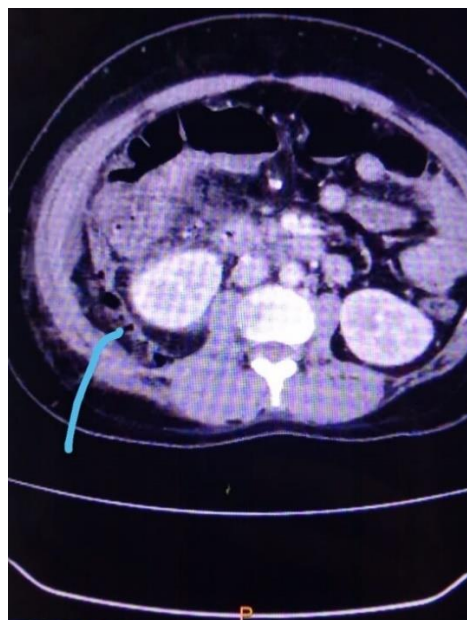

Fig. 1. Blue Arrow shows air in the retroperitoneum

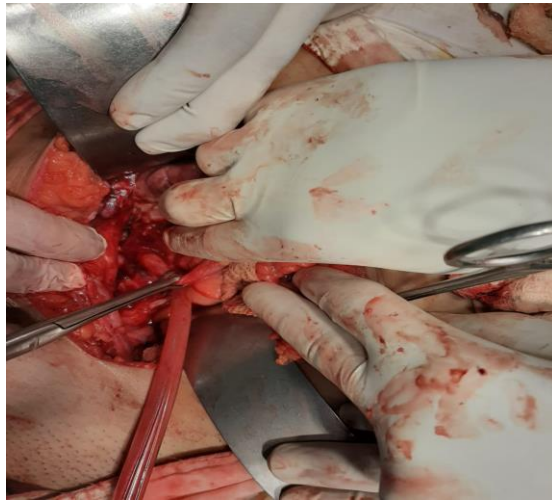


Fig. 2. Appendix identified and held with babcock's forceps

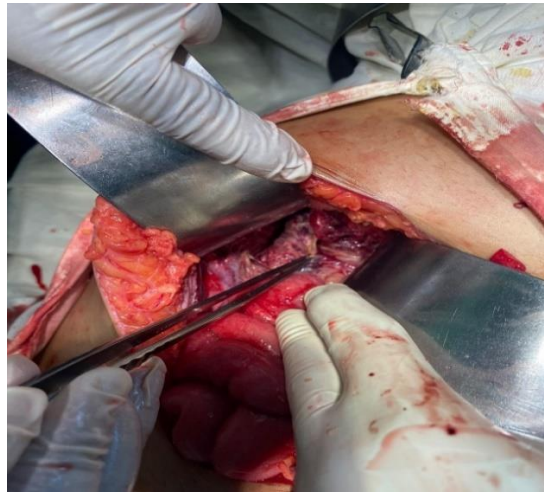

Fig. 3. Posterior peritoneum inflamed and necrotic

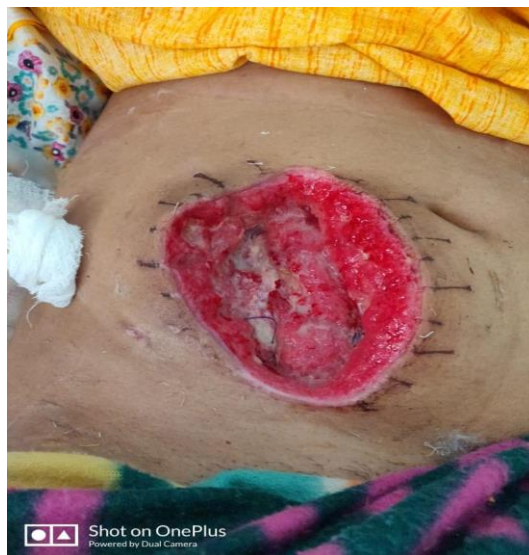

Fig. 4. Post-operative wound infection

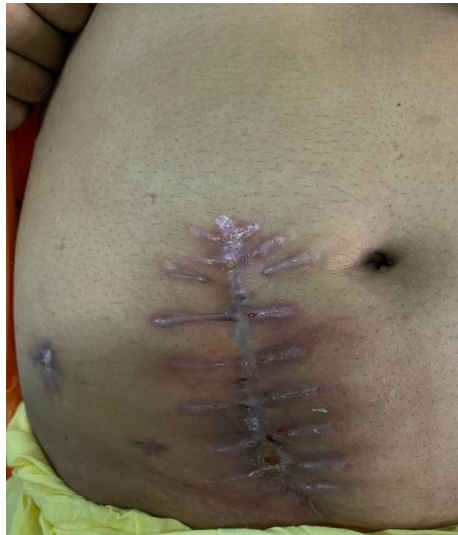

Fig. 5. Healing after secondary suturing

3. DISCUSSION

The most common abdominal emergency worldwide is acute appendicitis and its surgical treatment is effective with no adverse outcomes ensuring full recovery. Retroperitoneal abscess is one of the most dreaded and rare complication of acute appendicitis [4]. “There is an atypical presentation to this thereby leading to a delay in diagnosis. The abscesses can be located in various anatomical spaces, forming perinephric, psoas, retroperitoneal, thigh, and even abdominal wall abscesses” [5]. “The various positions and peritoneal fixation of the normal appendix, the direction in which the diseased appendix was pointing, and the route of spread of necrotic debris after the appendiceal perforation are all likely to explain the formation of the various types of abscess” [6].

“Retroperitoneal abscesses was earlier diagnosed based on physical findings such as a positive psoas stretch test, or on indirect evidence of inflammation or a mass effect revealed by conventional radiological studies, including subcutaneous emphysema, a blurred psoas shadow, or external compression of the ascending colon. A CT scan provides clear images of the retroperitoneal musculature and allows the identification of specific lesions whereas conventional radiological studies have relatively low diagnostic sensitivity” [7].

“After obtaining a diagnosis, a decision must be taken regarding operative or non-operative management. Percutaneous drainage of the abscess has the advantage of being less

invasive than surgery” [8]. “But most patients are usually in critical condition requiring prompt action by complete drainage of multiple loculated abscesses, which are unlikely to be achieved by percutaneously or laparoscopically” [9]. “Surgery is the mainstay of treatment for this group of patients and strong antibiotics should be used against severe infections in these patients. Even with proper management, a long hospital stay with slow recovery seems inevitable, as all of the survivors were hospitalized for at least 2 weeks” [6].

4. CONCLUSION

Therefore, we conclude that the formation of complicated retroperitoneal abscess involving the thigh, psoas muscle, perinephric space, and even the lateral abdominal wall is well recognized as a serious complication of perforated acute appendicitis. Perforated acute appendicitis can manifest as complicated retroperitoneal abscess without remarkable abdominal symptoms; thus, it is necessary to maintain a high index of suspicion in a patient with symptoms of retroperitoneal infection. A CT scan should be obtained to evaluate the possible origin and extent of the infection. Surgical drainage of the abscess is more effective than percutaneous drainage.

CONSENT

As per international standards or university standards, patient(s) written consent has been collected and preserved by the author(s).

ETHICAL APPROVAL

As per international standards or university standards written ethical approval has been collected and preserved by the author(s).

COMPETING INTERESTS

Authors have declared that no competing interests exist.

REFERENCES

1. Kloping Y, Putri RC. Atypical Presentation of Acute Appendicitis: A Case Report. The New Ropanasuri : Journal of Surgery. 2020 Dec 18;5(2):42–4.
2. Altemeier WA. Retroperitoneal Abscess. Archives of Surgery. 1961 Oct 1;83(4):512.
3. Hsieh CH, Wang YC, Yang HR, Chung PK, Jeng L Bin, Chen RJ. Retroperitoneal abscess resulting from perforated acute appendicitis: Analysis of its management and outcome. Surg Today. 2007 Sep; 37(9):762–7.
4. Nanavati AJ, Nagral S, Borle N. Retroperitoneal Perforation of the Appendix Presenting as a Right Thigh Abscess. Case Rep Surg. 2015;2015:1–3.
5. Hsieh C-H, Wang Y-C, Yang H-R, Chung P-K, Jeng L-B, Chen R-J. Extensive retroperitoneal and right thigh abscess in a patient with ruptured retrocecal appendicitis: An extremely fulminant form of a common disease. World J Gastroenterol. 2006;12(3):496.
6. Hsieh CH, Wang YC, Yang HR, Chung PK, Jeng LB, Chen RJ. Retroperitoneal abscess resulting from perforated acute appendicitis: analysis of its management and outcome. Surgery today. 2007 Sep;37: 762-7.
7. Mayumi T, Yoshida M, Tazuma S, Furukawa A, Nishii O, Shigematsu K, et al. The Practice Guidelines for Primary Care of Acute Abdomen 2015 Special Articles. Journal of General and Family Medicine. 2016;17.
8. Van Sonnenberg MD, E, Wittich MD, GR, Goodacre MD, BW, Casola MD, G, D'Agostino MD, HB. Percutaneous Abscess Drainage: Update. World J Surg. 2001 Mar 28;25(3):362–9.
9. Chan DS, Saklani A, Shah PR, Haray PN. Laparoscopic drainage of retroperitoneal abscess secondary to pyogenic sacroiliitis. The Annals of The Royal College of Surgeons of England. 2010 May;92(4): e32–4.

© 2023 Dey and Shyam; This is an Open Access article distributed under the terms of the Creative Commons Attribution License (<http://creativecommons.org/licenses/by/4.0>), which permits unrestricted use, distribution, and reproduction in any medium, provided the original work is properly cited.

Peer-review history:

The peer review history for this paper can be accessed here:
<https://www.sdiarticle5.com/review-history/109889>