



# **A Case Report of USG Guided Spinal Anaesthesia in a Patient with Kyphoscoliosis**

**Sheetal Madavi<sup>a‡</sup>, Kota Sneha<sup>a†\*</sup>, Neeta Verma<sup>a‡</sup>, Nikhil Akhijom<sup>a‡</sup>  
and Jui Jadhav<sup>a#</sup>**

<sup>a</sup> Department of Anaesthesia, JNMC, Wardha, India.

## **Authors' contributions**

*This work was carried out in collaboration among all authors. All authors read and approved the final manuscript.*

## **Article Information**

DOI: 10.9734/JPRI/2021/v33i62A35199

## **Open Peer Review History:**

This journal follows the Advanced Open Peer Review policy. Identity of the Reviewers, Editor(s) and additional Reviewers, peer review comments, different versions of the manuscript, comments of the editors, etc are available here: <https://www.sdiarticle5.com/review-history/79749>

**Case Study**

**Received 20 October 2021**  
**Accepted 26 December 2021**  
**Published 28 December 2021**

## **ABSTRACT**

Patients with spine abnormalities like kyphoscoliosis are very much challenging for the spinal anaesthesia. We report an interesting and challenging case of thoracolumbar kyphoscoliosis patient posted for supra pubic catheterization. We planned to do USG guided spinal anaesthesia. Lumbar vertebra and intervertebral spaces of the patient were scanned with help of ultrasound. For spinal access L2-L3 intervertebral space through which dura can be observed is selected. Patient had good spinal effect and procedure is uneventful. This case demonstrates that spinal anaesthesia performed under the guidance of ultrasonography will be successful in case of severe kyphoscoliosis.

**Keywords:** Spinal anaesthesia; ultra sonography; kyphoscoliosis.

## **1. INTRODUCTION**

Kyphoscoliosis is defined as a deviation of normal curvature of the spine in the sagittal and

coronal planes and can include a rotation of the spinal axis. It is a lateral and forward bending of spine at thoracolumbar region [1]. The most common etiology is idiopathic, other

<sup>‡</sup>Asso. Professor;

<sup>†</sup>Junior Resident;

<sup>‡</sup>Senior Resident;

<sup>#</sup>Assistant Professor;

<sup>\*</sup>Corresponding author: E-mail: sneha144.kota@gmail.com;

causes include neuromuscular, congenital or traumatic.

Patients with kyphoscoliosis presents with axially rotated vertebral bodies, with their spinous processes facing into the concavity of the curve and decrease in inspiratory capacity, functional total lung capacity, residual capacity, and vital capacity. The abnormal thoracic cavity leads to decrease in chest wall compliance [2]. There will be decrease in ventilator perfusion mismatch which leads to arterial hypoxemia. It may also cause pulmonary vascular resistance causing pulmonary hypertension. This gives challenge to an anesthesiologist in both regional anesthesia and general anesthesia [3].

The abnormal spine anatomy is a challenge to give regional anesthesia i.e subarachnoid block. The degree of spinal rotation is difficult to estimate clinically and by xrays.

Ultrasonography can helps in estimating both depth and location of epidural space and this can be used in operating room space. There is a study previously done on calculating vertebral body rotation and the reported values are correlated well with radiologically derived calculations.

Herein, we aimed to evaluate the advantages of ultrasonography guided spinal anesthesia in our patient with kyphoscoliosis posted for supra pubic catheterization.

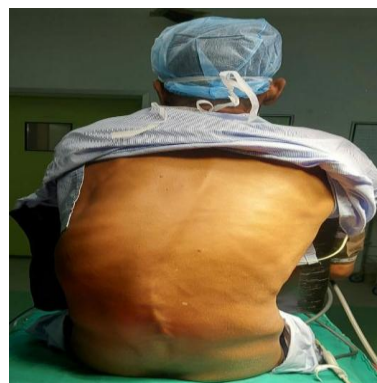## 2. CASE REPORT

A 55 year old male patient presented with non healing ulcer over scrotal region and diagnosed urethral fistula posted for suprapubic catheterization. On preoperative evaluation patient is having kyphoscoliosis since birth. Patient don't have any other significant history. On examination patient vitals were stable. On airway assessment mouth opening is -adequate with mallampatti class 2, with normal range of neck movements.

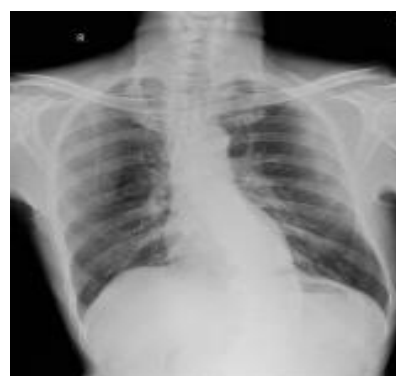Patients all routine that is complete blood count, LFT and KFT are within normal limits. Pulmonary function tests showed mild to moderate restrictive pattern. The surgery was planned under spinal anesthesia. Patient was nil by mouth for 8hrs for solids and 2hrs for water. Informed and written consent obtained from patient and his family.

Intra operative management: patient was taken inside after confirming the nil by mouth status. Monitors were attached, patient vitals are with in normal limits. Peripheral venous access taken with 18 g intracath on right forearm. Patient was prepared for spinal anesthesia in sitting position, ultra sound machine is arranged. Patient spine was sterilized with betadine and spirit and draped. Ultra sound machine is taken near to the patient and the probe is draped with sterilized glove.

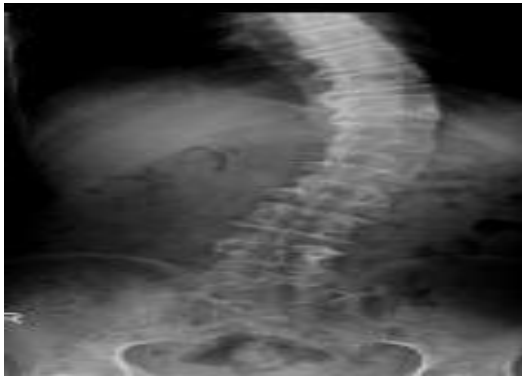
Lumbar vertebrae and intervertebral spaces of the patient were scanned with an 8MHz headpiece of the ultrasound. Transverse processes of lumbar vertebrae, and dura were tried to be detected using a convex vertical probe. For spinal access, L2- L3 intervertebral space through which dura can be observed was selected. Under the guidance of Ultrasound, subarachnoidal space was entered at the first attempt using a 23 G quinckes spinal needle directed 45°-60- degrees cephalad. After observing outflow of cerebrospinal fluid, 3.4 ml of bupivacaine heavy (5 mg/ml) was injected through the spinal needle slowly.



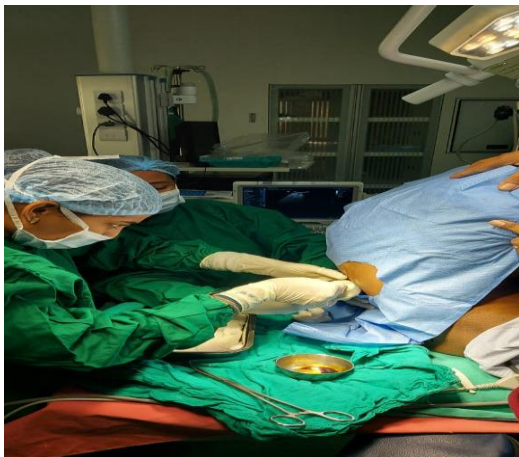**Fig. 1. On examination of spine a lateral curvature present with kyphoscoliosis**



**Fig. 2. X-ray image**



**Fig. 3. X-ray of spinal chord**



**Fig. 4. Operative period**

The procedure was uneventful. Once procedure was done patient was shifted to post anesthesia Care Unit. Vitals were monitored and patient was stable. In the postoperative period, the effect of spinal anesthesia lasted for 2 hours. For pain management, the patient was given tramadol and paracetamol according to the intensity of pain.

### 3. DISCUSSION

kyphoscoliosis is a deformity of a spine with abnormal curvature at vertebral column both sagittal and coronal planes. It is a combination of kyphosis and scoliosis.

Spinal deformities present with functional and physical problems to the patient and to the anesthesiologists in terms of planning the anesthesia technique. Kyphoscoliosis patients will have reduction in lung volumes and reduction in both vital and total lung capacities. Patients may land up in severe restrictive lung disorders, because of these manifestations patients will always land in post operative complications.

Due to problems associated with the respiratory system, spinal anesthesia is used widely, though technically difficult. Even with spinal anesthesia the blockade of nerves is a challenge. There can be partial blockade. Douglas et al. described an asymmetric block with severe scoliosis patient. The patient had incomplete block on left side, satisfactory block is only achieved by tilting patients bed to left side.

Spinal anesthesia itself is a challenge as patients lungs are compromised, further compromise will happen if the blockade reaches intercostal muscles which leads to further complications followed by postoperative complications.

There are case reports of achieving adequate spinal anesthesia by looking radiographs. Radiographs may help in assessing the location and extent of vertebral involvement. Moe and nash assessed vertebral rotation through spinal radiographs but to know the extent and and to evaluate we need more familiarity and more information on radiographs and it is very difficult to correlate with clinical situation [4].

Ultrasonography can help in this type of situations as it is more realtime, accessible tool. it helps in studying the anatomy of the spine [5]. Rather than palpation ultrasonography will help us in identifying interspaces more accurately. The main limitation of ultrasonography in neuro axial blockade is the narrow acoustic shadow between adjacent laminae. Still, it is helpful in preprocedural examination. Watson et al done a study which showed the anesthesiologist who received minimal instructions on ultrasonography identified L3-L4 interspace correctly in 13 patients out of 17 patients in nonpregnant patients in sitting position [1]. Weed et al. suggested ultrasonography helps in decision making by preprocedural examination [7]. Ultrasound identifies posterior longitudinal ligament which is a reliable indicator to get approach for intra thecal space. With the above information we want to do subarachnoid block as patient is undergoing lower extremity surgery under the guidance of ultra sonography.

We achieved desired blockade with the help of ultrasound by giving 0.5% heavy bupivacaine. We didn't experience any asymmetrical block to our patient. No intraoperative events are noted. Patient is stable and no postoperative complications were seen.

As our patient is a kyphoscoliosis patient and their respiratory system will be in compromised state and spinal anesthesia itself can cause further compromise if the blockade reach to intercostal muscles care was taken after giving spinal we tried to avoid the level getting higher by giving adequate amount of drug and giving proper position after securing the neuro axial blockade.

Ultrasound helps anesthesiologist in achieving proper blockade and it also helps patient by avoiding multiple pricks and pain. Kyphoscoliosis patients often lands up in getting multiple pricks in normal palpation methods which cause severe pain, trauma and mental stress to the patient. Ultrasound guided spinal anesthesia helps to avoid all these problems. This gives mental peace and satisfaction to the anesthesiologist as their patient will be in very minimal pain.

#### 4. CONCLUSION

We conclude that ultrasound guide subarachnoid block helps in achieving successful blockade with less number of attempts and gives comfort to patient and to the doctor.

#### CONSENT AND ETHICAL APPROVAL

As per international standard or university standard guideline Patient's consent and ethical approval has been collected and preserved by the authors.

#### COMPETING INTERESTS

Authors have declared that no competing interests exist.

#### REFERENCES

1. Watson MJ, Evans S, Thorp JM. Could ultrasonography be used by an

- anaesthetist to identify a specified lumbar interspace before spinal anaesthesia? Br J Anaesth. 2003 Apr;90(4):509-11. DOI: 10.1093/bja/aeg096 PMID: 12644427.
2. Suzuki S, Yamamuro T, Shikata J, Shimizu K, Iida H. Ultrasound measurement of vertebral rotation in idiopathic scoliosis. J Bone Joint Surg Br. 1989 Mar;71(2):252-5. DOI: 10.1302/0301-620X.71B2.2647754 PMID: 2647754.
3. Libby DM, Briscoe WA, Boyce B, Smith JP. Acute respiratory failure in scoliosis or kyphosis: prolonged survival and treatment. Am J Med. 1982 Oct;73(4):532-8. DOI: 10.1016/0002-9343(82)90332-1 PMID: 6812420.
4. Nash CL Jr, Moe JH. A study of vertebral rotation. J Bone Joint Surg Am. 1969 Mar;51(2):223-9. PMID: 5767315.
5. Chin KJ, Perlas A, Singh M, Arzola C, Prasad A, Chan V, Brull R. An ultrasound-assisted approach facilitates spinal anesthesia for total joint arthroplasty. Can J Anaesth. 2009 Sep;56(9):643-50. DOI: 10.1007/s12630-009-9132-8 Epub 2009 Jun 23. PMID: 19548051.
6. Furness G, Reilly MP, Kuchi S. An evaluation of ultrasound imaging for identification of lumbar intervertebral level. Anaesthesia. 2002 Mar;57(3):277-80. DOI: 10.1046/j.1365-2044.2002.2403\_4.x PMID: 11892638.
7. Weed JT, Taenzer AH, Finkel KJ, Sites BD. Evaluation of pre-procedure ultrasound examination as a screening tool for difficult spinal anaesthesia\*. Anaesthesia. 2011;66(10):925-30. DOI: 10.1111/j.1365-2044.2011.06834.x. Epub 2011 Jul 25. PMID: 21790522.

© 2021 Madavi et al.; This is an Open Access article distributed under the terms of the Creative Commons Attribution License (<http://creativecommons.org/licenses/by/4.0>), which permits unrestricted use, distribution, and reproduction in any medium, provided the original work is properly cited.

*Peer-review history:*  
The peer review history for this paper can be accessed here:  
<https://www.sdiarticle5.com/review-history/79749>