

Case Report and Review of Glandular Odontogenic Cyst in Anterior Maxilla- A Histopathologic Perspective

B. R. Premalatha^{1*}, Sohani Maroli², Usha Hegde¹ and T. M. Kalappa³

¹Department of Oral Pathology and Microbiology, J.S.S Dental College and Hospital, J.S.S University, Mysuru, Karnataka, India.

²Department of Conservative Dentistry and Endodontics, St. Joseph Dental College, Eluru, Andrapradesh, India.

³Consultant Oral and Maxillofacial Surgeon, Mysuru, Karnataka, India.

Authors' contributions

This work was carried out in collaboration between all authors. Author BRP produced the initial draft, literature search and designed the outline. Author SM managed the literature search. Author UH corrected the manuscript and author TMK managed the operative procedure. All authors read and approved the final manuscript.

Article Information

DOI: 10.9734/ARRB/2016/25067

Editor(s):

(1) Ibrahim Farah, Jackson State University, Mississippi, USA.

(2) George Perry, Dean and Professor of Biology, University of Texas at San Antonio, USA.

Reviewers:

(1) J. Anshuman, Mahatma Gandhi Medical University, India.

(2) Sonal Grover, Christian Dental College, CMC, Ludhiana, India.

Complete Peer review History: <http://sciencedomain.org/review-history/14192>

Case Study

Received 16th February 2016

Accepted 2nd April 2016

Published 15th April 2016

ABSTRACT

Glandular odontogenic cyst is a rare odontogenic jaw cyst which exhibits a locally aggressive behaviour with high recurrence rate. It is a relatively new entity that was first described in 1987. Because of the paucity of reported cases, there is no consensus or established protocols about many aspects of management of this lesion. In this article, we present a case of glandular odontogenic cyst in maxilla in a 48 year old male patient and focus on the review of clinico-pathologic features and differential diagnosis, which can be often challenging.

Keywords: Glandular odontogenic cyst; jaw cyst; recurrence; sialo-odontogenic cyst.

*Corresponding author: E-mail: prema.raaj@gmail.com;

1. INTRODUCTION

Glandular odontogenic cyst (GOC) is an uncommon developmental jaw cyst of odontogenic origin [1]. It is suggested to originate from the remnants of the dental lamina [2]. GOC is relatively a new entity. It was first described in 1987 by Padyachee and Van Wyk, as "sialo-odontogenic cyst". Several other names were formerly used to entitle GOC in the literature, including the polymorphous odontogenic cyst and the mucoepidermoid odontogenic cyst. Gardner et al. introduced the now widely accepted term, "glandular odontogenic cyst". GOC was later listed in the histologic typing of odontogenic tumors by the World Health Organization (WHO) in 1992 [3].

It is defined as a cyst arising in the tooth-bearing areas of the jaws and characterized by an epithelial lining with cuboidal or columnar cells both at the surface and lining crypts or cyst-like spaces within the thickness of the epithelium [4]. Clinically, the most common site of occurrence is mandibular anterior region, presenting as an asymptomatic slow growing swelling. GOC occurs mostly in the middle age and has a slight male predilection. Radiologically, these cysts may be unilocular or multilocular with a well-defined border [1]. Tooth displacement, root resorption and an association with unerupted tooth is also noted [5].

GOC is characterized by a cyst wall lining of non-keratinized epithelium, with papillary projections,

nodular thickenings, mucous filled clefts, and 'mucous lakes.' It also includes cuboidal basal cells, sometimes vacuolated. It is a cyst having an unpredictable and potentially aggressive behaviour. It also has the propensity to grow to a large size and shows tendency to recur [1]. Because of the rarity of this lesion, and few cases being reported in the literature, there is no defined management protocol [6]. Treatment of GOC includes curettage and enucleation, although some authors believe marginal resection to be more reliable treatment, due to tendency of the cyst to recur after curettage and enucleation [1].

2. CASE REPORT

A male patient aged 48 years reported with a swelling in the anterior maxilla. On clinical examination, teeth 11 and 12 were root canal treated. OPG revealed a unilocular radiolucent lesion with well-defined margins measuring approximately 3 x 4 cm in the periapical region of 11, 12, 13 and 21 extending superiorly into the nasal cavity (Fig. 1).

The lesion was provisionally diagnosed as radicular cyst and a differential diagnosis of keratocystic odontogenic tumor was considered. An incisional biopsy was performed. Specimen was tan to reddish in colour with irregular shape and surface. One of the bits showed nodular thickening. The specimen was subjected to routine processing.

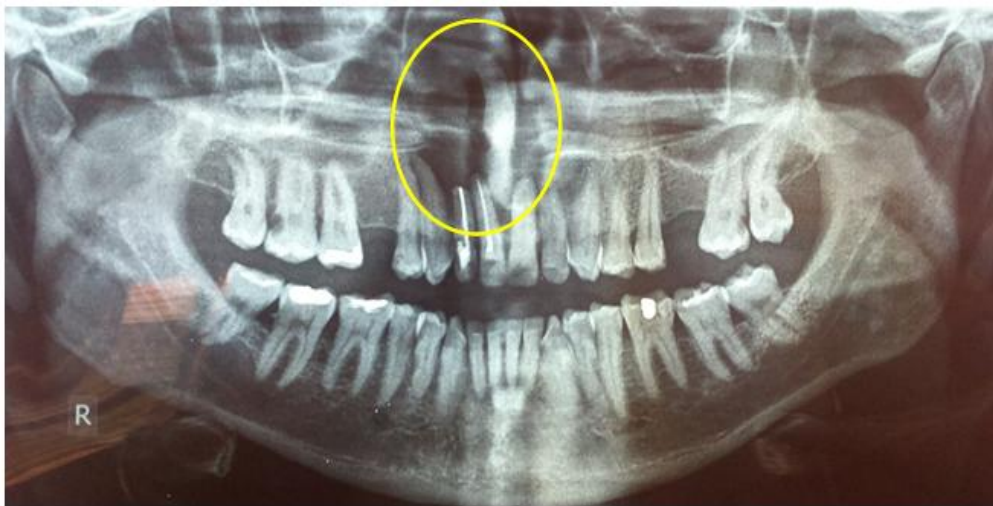

Fig. 1. Well defined radiolucency i.r.t 11, 12, 13 and 21 extending into the nasal floor

H and E stained sections revealed a cystic lining made up of non-keratinized stratified squamous epithelium of variable thickness lacking rete ridges. Epithelium showed focal intraluminal proliferations. Numerous duct-like spaces lined by cuboidal cells were seen. Few cells showed mucous cell differentiation. Superficial cells showed cilia and basal cells showed reverse polarity in focal areas. The connective tissue was fibrous and showed moderately dense chronic inflammation and few resorbing bone trabeculae. (Figs. 2, 3, 4) Based on the above findings a diagnosis of GOC was made. The lesion was surgically removed and follow-up of the patient since one year has been uneventful.

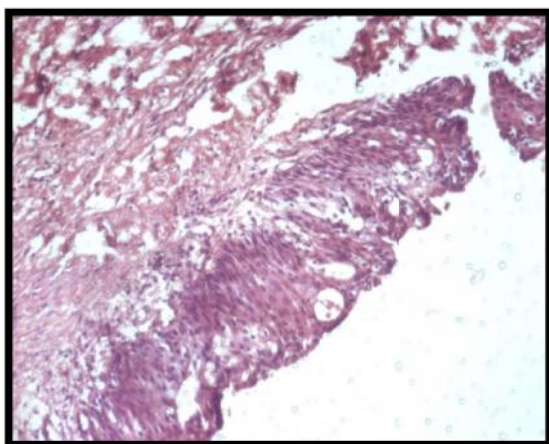


Fig. 2. Non keratinized, stratified squamous lining epithelium consisting of duct-like spaces lined by cuboidal cells supported by connective tissue stroma. (H & E 10X)

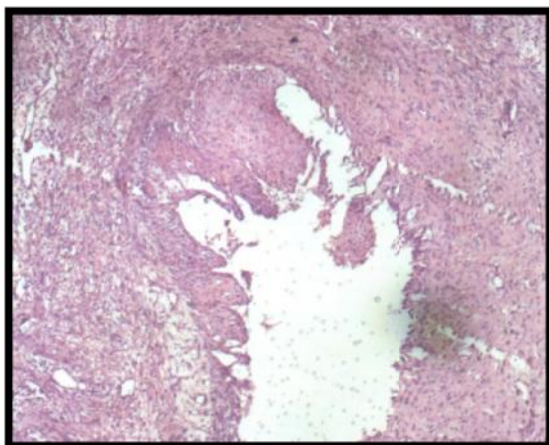


Fig. 3. Cystic lining epithelium showing variable thickness and intraluminal proliferation. (H & E 4X)

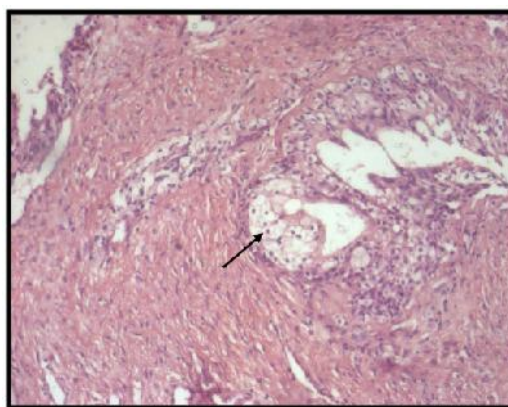


Fig. 4. Mucous cells within the lining epithelium mimicking a gland. (H & E 10X)

3. DISCUSSION

A case of GOC, a rare developmental cyst of the jaws, in a 48 year old male patient is hereby presented. GOC is a rare lesion with a frequency rate of only 0.012% to 1.3% of all the jaw cysts and its prevalence is 0.17% [1]. Only 114 cases of GOC have been reported in the literature [1,7].

Similar to previous reports, our case was in agreement with the gender predilection, mean age and presenting symptom as swelling. The radiological features were also in accordance with previous reports, showing a well-defined radiolucency with well-defined borders. The disagreement was related to site, the literature shows predilection for mandibular anterior region while the present case was reported in the maxillary anterior region. Other interesting clinical presentations of GOC reported in literature are: bilateral GOCs in the posterior [8] and anterior maxilla [9] and simultaneous occurrence of GOC and ameloblastoma in three cases [10].

Immunohistochemical studies using cytokeratin-7, 13, 14 and 19 and their positivity strongly support the odontogenic nature of GOC. The identification of osteodentin and negative reaction for EMA (Epithelial membrane Antigen) in the area of glandular structures suggest that these features are not of glandular origin and support the concept of odontogenic differentiation in GOC. The aggressive biologic behaviour of GOC and its propensity for recurrence might be associated with cell kinetics in the lining epithelium. Certain studies have reported an increased Ki-67 index and decreased P53 positivity suggesting that GOC

lining displays increased proliferation, but not malignant transformation potential [1].

Histopathological features of the present case satisfied major and minor Kalpan et al. diagnostic criteria for GOC (Table 1) including presence of squamous epithelial lining with flat interface, intraluminal proliferation and no basal palisading, variation in thickness of the lining, mucous cells, intraepithelial duct-like structures as major criteria and presence of ciliated cells, as minor criteria.

Table 1. Diagnostic criteria for GOC [11]

Major criteria (Must be present for diagnosis)	Minor criteria (Criteria that supported the diagnosis but not mandatory)
Squamous epithelial lining with a flat interface with the connective tissue wall lacking basal palisading	Papillary proliferation of the lining epithelium
Epithelium exhibiting variations in thickness along the cystic lining with or without epithelial “spheres,” “whorls,” or focal luminal proliferation	Ciliated cells
Cuboidal eosinophilic cells or “hobnail” cells	Multicystic or multiluminal architecture
Mucous (goblet) cells with intraepithelial mucous pools, with or without crypts lined by mucous-producing cells	Clear or vacuolated cells in the basal or spinous layers
Intraepithelial glandular, microcystic, or duct-like structures	

Rare histopathologic findings reported in literature include: association with ameloblastoma, squamous odontogenic tumor-like hyperplasia, solid epithelial down growths into the cyst wall, satellite microcysts, hyaline bodies and epithelial ghost cell calcification [9].

Histopathological differential diagnosis of GOC ranges from destructive malignant neoplasm

such as central mucoepidermoid carcinoma (CMEC) which has potential to metastasize; to benign lesions such as lateral periodontal cyst (LPC) and botryoid odontogenic cyst (BOC) [1,3,9].

The cystic structures and mucous cells are prominent features in both GOC and CMEC [3]. However, superficial cuboidal cells, nodular epithelial thickenings and whorlings, ciliated cells, and intraepithelial microcyst or duct-like structures are not typical for CMEC [9]. Likewise, GOC will not demonstrate cellular atypia and areas of solid growth of epidermoid and/or intermediate cells as those in MECs [3,11]. Positivity for CK-18 and CK-19; decreased p-53 positivity and increased Ki-67 index in GOC when compared to CMEC and increased maspin (mammary serine protease inhibitor) expression in CMEC but not in GOC helps in distinguishing between the two lesions [1,3,9].

LPC is a developmental odontogenic cyst lined by thin non-keratinized epithelium and also exhibits focal epithelial thickenings and glycogen rich epithelial cells, similar to those observed in GOC. BOC is a locally aggressive polycystic variant of LPC, shows similar histomorphologic features with those of GOC, like epithelial plaques and areas of glycogen rich clear cells. However, the identification of ciliated epithelium and duct like spaces with mucous cells specifically differentiate it from LPC and BOC and favours the diagnosis of GOC [1,9]. The typical histological features in the present case helped us in ruling out the differentials and arrive at the final diagnosis of GOC.

At least 25% to 55% cases recur following curettage [9]. The aggressive biologic behaviour and propensity for recurrence might be associated with cell kinetics in the lining epithelium i.e. infoldings, microcysts and plaques which are suggestive of active cell proliferation. Incomplete removal due to multicystic configuration, thinness of the cyst wall, tendency of epithelium to separate from connective tissue or growth through cancellous spaces of bone may also account for its high recurrence rate [1,9,12].

The treatment of choice is still controversial and ranges from curettage, enucleation, en bloc and partial osteotomy. In view of high recurrence rate associated with conservative treatment of the cysts and their invasive potential, a more aggressive removal over conservative approach

is essential [1]. It is also imperative to follow up the patient carefully for several years, since cases have been reported as long as 7 years after original treatment [12,13]. In the present case too it was treated aggressively by wide surgical excision and is being followed up periodically.

4. CONCLUSION

In conclusion, this case report of GOC will add to the existing knowledge of these rare odontogenic cysts. Our case correlates with the existing literature that GOC affects the middle age group men more commonly. The glandular odontogenic cyst remains a rare lesion but should be considered in the differential diagnosis of unilocular and multilocular radiolucencies of the jaws.

COMPETING INTERESTS

Authors have declared that no competing interests exist.

REFERENCES

1. Krishnamurthy A, Sherlin HJ, Ramalingam K, Natesan A, Premkumar P, Ramani P, et al. Glandular odontogenic cyst: Report of two cases and review of literature. *Head and Neck Pathol.* 2009;3:153–158.
2. Asutay F, Acar AH, Yolcu Ü, Karadağ N, Geçör O. Glandular odontogenic cyst mimicking dentigerous cyst: A case report. *J of İstanbul University Faculty of Dentistry.* 2014;48(1):65-70.
3. Pornpop Rattana-Arpha, Ploi Yongvanijchit, Ekarat Phattarataratip. Glandular odontogenic cyst of the mandible: A case report and its potential diagnostic pitfalls. *International J of Oral and Maxillofacial Pathology.* 2013;4(2): 34-39.
4. Chung GC, Han WJ, Kim EK. A huge glandular odontogenic cyst occurring at posterior mandible. *Korean J Oral Maxillofac Radiol.* 2004;34:209-13.
5. MacDonald-Jankowski DS. Glandular odontogenic cyst: Systematic review. *Dentomaxillofacial Radiology.* 2010;39(3): 127.
6. Manzini M, Deon C, Corte LD, Bertotto JC, Abreu LB. Glandular odontogenic cyst: An uncommon entity. *Braz J Otorhinolaryngol.* 2009;75(2):320.
7. Kasaboglu O, Basal Z, Usubütün A. Glandular odontogenic cyst presenting as a dentigerous cyst: A case report. *J Oral Maxillofac Surg.* 2006;64(4):731-3.
8. Amberkar VS, Jahagirdar A, Mujib ABR. Glandular odontogenic cyst: Report of an unusual bilateral occurrence. *Indian J Dent Res.* 2011;22:364.
9. Asthana A, Singh AK. Bilateral glandular odontogenic cyst of the maxilla: A rare case report and review of literature. *Int J Med and Dent Sci.* 2014;3(2):512-517.
10. Naik. LRK, Agarwal R, Amberkar VS, Mujib ABR. A rare variant of ameloblastoma associated with a glandular odontogenic cyst. *Indian J of Pathology and Microbiology.* 2008;51(4): 576-577.
11. Tambawala SS, Karjodkar FR, Yadav A, Sansare K, Sontakke S. Glandular odontogenic cyst: A case report. *Imaging Science in Dentistry.* 2014;44:75-9.
12. Nair RG, Varghese IV, Shameena PM, Sudha S. Glandular odontogenic cyst: Report of a case and review of literature. *J Oral Maxillofac Pathol.* 2006;10:20-23.
13. Kaplan I, Gal G, Anavi Y, Manor R, Calderon S. Glandular odontogenic cyst: Treatment and recurrence. *Journal of Oral and Maxillofacial Surgery.* 2005; 63(4):435-441.

© 2016 Premalatha et al.; This is an Open Access article distributed under the terms of the Creative Commons Attribution License (<http://creativecommons.org/licenses/by/4.0>), which permits unrestricted use, distribution, and reproduction in any medium, provided the original work is properly cited.

Peer-review history:
The peer review history for this paper can be accessed here:
<http://sciencedomain.org/review-history/14192>