

Bicornuate Unicollis Uterus in Recurrent Spontaneous Abortion- A Case Report

MANAS SINGH BAGHEL¹, SUREKHA TYADE², YUGANSHU BISEN³

ABSTRACT

Bicornuate Unicollis uterus is a congenital uterine anomaly due to malformation of the paramesonephric ducts, also known as Müllerian ducts, presenting in 3%-5% of the general population. It is relatively rare to associate uterine anomalies and pregnancy outcomes. Patients are often asymptomatic but can present with secondary infertility, disturbances in menstruation, recurrent early and late pregnancy loss, and intrauterine growth restrictions and deaths which can be a sign for the diagnosis of the abovementioned condition. Here, we discuss a case of a 28-year-old female, of low socioeconomic status, presented with a history of white-coloured vaginal discharge and two spontaneous abortions in the last two years. On gynaecological examination, a polyp of 2x2 cm was observed over the anterior lip of the cervix, with curdy white discharge present on per speculum examination. On per vaginum examination, the uterus was found to be anteverted and anteflexed, and the fornices were free. Magnetic Resonance Imaging (MRI) revealed it as a bicornuate uterus, and the patient was managed with septum resection and counseled for a successful future pregnancy outcome.

Keywords: Congenital uterine anomaly, Infertility, Magnetic resonance imaging

CASE REPORT

A 28-year-old married female resident of Maharashtra, who is Hindu and works as a homemaker, presented to the gynecology outpatient department on January 20th, 2023, with complaints of white vaginal discharge that had been progressively worsening for the past two years. She also reported irregular menstrual cycles with increased flow for 2-3 months, as well as mild abdominal pain, intermenstrual pain, burning sensation during urination, and dyspareunia. The patient's obstetric history revealed that she and her partner had been married for three years and had conceived twice, but both pregnancies resulted in intrauterine deaths (IUD). Her obstetric score was P1A2, with the first abortion occurring 2 years ago at six months gestation, and the second abortion occurring 1 year ago at eight months gestation. During the second abortion, the patient received two units of blood, but dilation and curettage was not performed.

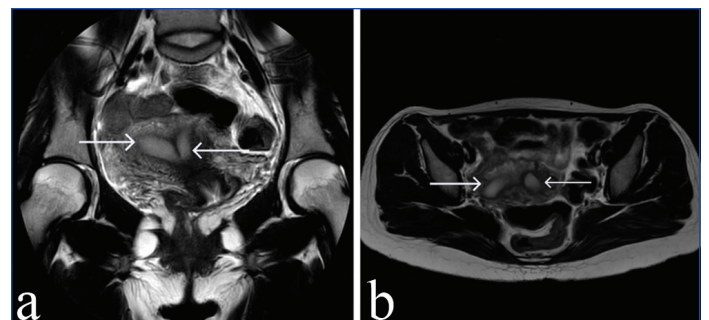
According to maternal history, she had her last menstrual period on 04th January 2023. Her premenstrual history was irregular, lasting 7-8 days every 1-2 months the flow was average with no clots. She had no dysmenorrhea, and was lactating. Also, according to past history, the patient had undergone a blood transfusion once i.e., two units of packed red blood cells during the second abortion. Following the transfusion, there was swelling of the face and body. No history of any surgical illness or medical illness in the past. The family and personal history was not significant.

The patient underwent a general examination and was afebrile to touch. The patient had an average build, weighed 56 kg, height of 156 cm tall, and had a Body Mass Index (BMI) of 23 kg/m². Her pulse was 92/min, respiratory rate was 14/min, and her blood pressure was 122/84 mm Hg. The patient's systemic examinations were normal. On gynaecological examination, a polyp of 2x2 cm was observed over the anterior lip of the cervix, with curdy white discharge present on per speculum examination. On per vaginum examination, the uterus was found to be anteverted and anteflexed, and the fornices were free.

Laboratory investigations showed that the HIV and HBsAg tests were negative, and the complete blood count revealed a haemoglobin level of 10.3 g/dL. The thyroid function tests revealed normal fT₃, fT₄, and TSH levels. Also, the kidney function tests and liver function tests were within normal limits, but the prolactin level was elevated (31 ng/mL). The patient's blood group was B+ve.

An ultrasound scan of the abdomen and pelvis revealed a partially distended gallbladder, normal liver, pancreas, and spleen, normal renal function, a bulky uterus measuring 8.1x7.6x4.4 cm, and free fluid in the pouch of Douglas. There is evidence of endometrium in the body of the uterus bifurcating into two horns cranially with intervening tissue consistent with normal myometrium suggestive of uterine duplication (bicornuate/septate uterus).

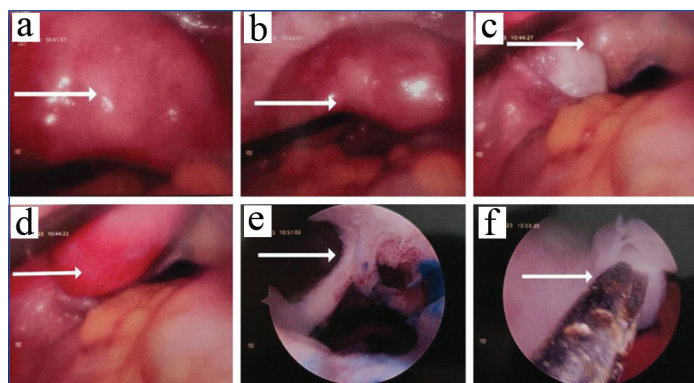
On MRI, plain and contrast [Table/Fig-1], the uterus was retroflexed, normal in size and signals, and showed normal enhancement. There is evidence of a bicornuate uterus with a normal appearing both the horns and single cervix. The right horn measures- 5x3.5 cm, and the left horn measures- 5.2x3 cm. There is no focal mass lesion within the uterus. The Junctional zone- is 4-5 mm in both horns endometrial thickness of 14 mm in the right horn and 9 mm in the left horn. The cervix appears bulky. The vagina, ovaries, pouch



[Table/Fig-1]: MRI Pelvis images showing a bicornuate uterus in two different sections; a) T2-weighted coronal section of MRI Pelvis depicting two horns of the bicornuate uterus; b) T2-weighted transverse section of MRI Pelvis depicting two horns of the bicornuate uterus (white arrows).

of Douglas, urinary bladder, and rectum appear normal. The MRI gives the impression of Bicornuate unicollis uterus (partial) with a normal appearing both horns.

The patient was managed with a combination of intravenous antibiotics, anti-inflammatory medications, and probiotics to manage the white discharge per vagina, intermenstrual pain, and mild abdomen pain. The patient was scheduled for Diagnostic Hysteroscopy (DHL) [Table/Fig-2] under general anaesthesia for the indication of secondary infertility with a bicornuate uterus. In laparoscopy, all the structures were visualised and appeared normal. However, during vaginoscopy, all fornices were normal. The endocervical canal was visualised and was normal. The endometrial cavity appears irregular and hyperaemic, there was a complete uterine septum, and the two uterine cavities were visualised. Normal endometrium was seen over the lateral walls of the uterine cavity. Bilateral ostia could not be visualised due to excessive fluffy endometrium. Then septal resection was done, with 1-1.5 cm septum left over the fundal region. Ports were removed under vision. Pneumoperitoneum was deflated. Port site closure and curettage was done. Haemostasis was ensured. The procedure was uneventful, and the patient withstood the procedure well. On the second postoperative day, the Foley's catheter was removed, urine was passed, and the dressing was checked on the seventh postoperative day.



[Table/Fig-2]: Intraoperative images of the DHL procedure. a) Bicornuate uterus; b) Bicornuate uterus; c) Left-side fallopian tube spillage seen; d) Right-side fallopian tube spillage seen; e) Uterine septum seen; f) Septal resection done.

The patient was discharged on the 7th postoperative day and was advised to keep a high-protein diet and drink plenty of fluids along with sufficient rest. Also, she was asked to have a follow-up after 15 days or in case of any emergency. Medications such as antibiotics, proton pump inhibitors, protein powder, anti-ulcer gel, and multivitamins were given to her.

DISCUSSION

Bicornuate uterus is relatively rare, accounting for approximately 3%- 5% of all uterine anomalies [1]. Out of all the types of congenital uterine anomalies, the bicornuate uterus is one of the commonest types. It is a condition resulting from malformation of Müllerian ducts fusion. The exact aetiology is not yet known but is often associated with the genetic disposition and abnormal stimulation of hormones, although congenital uterine anomalies are often clinically associated with infertility, early and late pregnancy loss, and spontaneous abortion, it does not prevent pregnancy but increase the odds of the patient reaching full-term pregnancy [2].

Approximately, 10-15% of couples of reproductive age worldwide are commonly affected by infertility [3]. While many infertility cases are due to male factors or ovulatory dysfunction, a significant proportion are attributed to uterine anomalies such as the bicornuate unicollis uterus [4]. Also, the major cause of spontaneous abortions is the bicornuate uterus, 62.5% of females with a bicornuate uterus have a chance of alive birth and the rest 25% have a risk of spontaneous abortions or preterm death [5]. Spontaneous abortion commonly

known as miscarriage is defined as losing a pregnancy before the 20th week of gestation. Being a common complication of early pregnancy, occurring in approximately 10-20% of all clinically recognised pregnancies, several factors including uterine anomalies can increase the risk of spontaneous abortion [6]. The abnormal uterine shape and reduced uterine capacity associated with a bicornuate uterus can lead to implantation failure, poor placental development, and cervical incompetence, increasing the risk of spontaneous abortion [7].

Also, the patient's poor socio-economic condition, as well as inadequate counseling for the patient and her family, are important factors that can hinder successful outcomes. Patients may not follow up due to fear of high treatment costs. Therefore, it is important to properly counsel the patient and emphasize the importance of follow-up for successful pregnancy outcomes. Additionally, patients should be enrolled in various schemes and programs to lessen the burden of treatment costs and subsequent follow-ups.

Diagnostic techniques such as MRI, hysterosalpingogram, hysteroscopy, ultrasonography (USG), and laparoscopy can be used to diagnose the bicornuate uterus with precision [8]. Although pregnancies in malformed uteri are often asymptomatic, they should be suspected in patients with recurrent miscarriages and malpresentation [9]. However, women diagnosed with a bicornuate uterus can still achieve successful pregnancies and have uneventful vaginal deliveries [10]. Early diagnosis and appropriate management of these uterine anomalies can improve the chances of successful pregnancy outcomes.

Unlike any other case, this anatomical delight presented with vaginal discharge and not with normal presentation of bicornuate uterine anomalies. On history taking and evaluation, it was discovered that the patient had undergone two recurrent spontaneous abortions in the past, which led to the suspicion of the obstetrician to evaluate further. On per vaginal examination, initially, perceived as a polyp at the anterior lip of the cervix but later on USG gave evidence of endometrial tissue bifurcating cranially into two horns. MRI proved to be an essential diagnostic tool for the final diagnosis and it was confirmed to be bicornuate unicollis uterus according to the American Society of Reproductive Medicine 2021 which could have been missed otherwise [11]. The case was not conventionally managed because not all uterine anomalies need surgical resection, but due to the past history of abortions, surgical intervention, i.e., DHL, was deemed to be the best modality of treatment because of its many advantages and fewer complications, to finally provide the patient with a successful chance of full-term delivery in future.

CONCLUSION(S)

This case report highlights the diagnostic importance of uterine anomalies early in females with a history of preterm delivery and recurrent pregnancy loss to facilitate appropriate management and improve reproductive outcomes. Women with a bicornuate unicollis uterus can still have successful pregnancies and vaginal deliveries with appropriate medical management and close monitoring. Therefore, a multidisciplinary approach involving obstetricians, gynaecologists, and reproductive medicine specialists is crucial for the optimal management of these patients. Due to the rarity of this condition among all uterine anomalies, we present this case not only as a treat to anatomists but as a conundrum for the obstetrician and gynaecologists to treat such cases of infertility and pregnancy-related issues.

REFERENCES

- [1] Grimbizis GF, Camus M, Tarlatzis BC, Bontis JN, Devroey P. Clinical implications of uterine malformations and hysteroscopic treatment results. *Hum Reprod Update*. 2001;7(2):161-74.
- [2] Shugaba AI, Mathew RM, Umar MB. Bicornuate uterus- a case report and literature review. *Hghl Med Res J*. 2006;4(2):49-51.

- [3] Mascarenhas MN, Flaxman SR, Boerma T, Vanderpoel S, Stevens GA. National, regional, and global trends in infertility prevalence since 1990: a systematic analysis of 277 health surveys. *PLoS Med.* 2012;9(12):e1001356.
- [4] Choudhary S, Jelly P, Mahala P. Successful outcome of pregnancy in bicornuate uterus: a case report. *Int J Reprod Contracept Obstet Gynecol.* 2019;8(10):4086-89.
- [5] Aliyu L, Abdullahi M. Bicornuate uterus mimicking ectopic pregnancy- A case report. *J West Afr Coll Surg.* 2012;2(1):84-90.
- [6] Alves C, Rapp A. Spontaneous abortion. In *Treasure Island (FL): StatPearls Publishing*; 2023.
- [7] Hosseinirad H, Yadegari P, Falahieh FM, Shahrestanaki JK, Karimi B, Afsharzadeh N, et al. The impact of congenital uterine abnormalities on pregnancy and fertility: a literature review. *JBRA Assist Reprod.* 2021;25(4):608-16.
- [8] Ibrahim HG, Muhammad SB, Hafsat AR, Umar UA. Bicornuate uterus presenting with recurrent pregnancy loss; the role of hysterosalpingography in the diagnosis: a report of two cases. *Int J Health Sci Res.* 2020;10(12):270-73.
- [9] Ikhuoriah T, Oboh D, Abramowitz C, Musheyev Y. Bicornuate uterus: A rare case of a viable full term pregnancy in the right uterine horn. *Radiol Case Rep.* 2023;18(6):2107-11.
- [10] Borgohain D, Srivastava S. Pregnancy in bicornuate uterus. *Int J Reprod Contracept Obstet Gynecol.* 2018;7(1):346-48.
- [11] Pfeifer SM, Attaran M, Goldstein J, Lindheim SR, Petrozza JC, Rackow BW, et al. ASRM müllerian anomalies classification 2021. *Fertil Steril.* 2021;116(5):1238-52.

PARTICULARS OF CONTRIBUTORS:

1. Medical Intern, Department of Obstetrics and Gynecology, Jawaharlal Nehru Medical College, Datta Meghe Institute of Higher Education and Research (Deemed to be) Wardha, Maharashtra, India.
2. Professor and Unit Incharge, Department of Obstetrics and Gynecology, Jawaharlal Nehru Medical College, Datta Meghe Institute of Higher Education and Research (Deemed to be) Wardha, Maharashtra, India.
3. Medical Intern, Department of Obstetrics and Gynecology, Jawaharlal Nehru Medical College, Datta Meghe Institute of Higher Education and Research (Deemed to be) Wardha, Maharashtra, India.

NAME, ADDRESS, E-MAIL ID OF THE CORRESPONDING AUTHOR:

Manas Singh Baghel,
Manas Netralaya, Seoni-480661, Madhya Pradesh, India.
E-mail: singhmanas18@gmail.com

PLAGIARISM CHECKING METHODS: [\[Jain H et al.\]](#)

- Plagiarism X-checker: Apr 19, 2023
- Manual Googling: May 03, 2023
- iThenticate Software: May 17, 2023 (1%)

ETYMOLOGY: Author Origin**EMENDATIONS:** 5**AUTHOR DECLARATION:**

- Financial or Other Competing Interests: None
- Was informed consent obtained from the subjects involved in the study? Yes
- For any images presented appropriate consent has been obtained from the subjects. Yes

Date of Submission: **Apr 18, 2023**Date of Peer Review: **May 08, 2023**Date of Acceptance: **May 26, 2023**Date of Publishing: **Jun 01, 2023**