



Inguinal Lymphadenopathy in Carcinoma Gall Bladder: An Unusual Site of Metastasis

**Ajas Ibrahim¹, Debanjan Sikdar¹, Sagar N Raut¹, Jaydeep Jain²,
Sweety Gupta^{1*}, Amit Gupta², Prashant Joshi³ and Manoj Gupta¹**

¹Department of Radiation Oncology, All India Institute of Medical Sciences (AIIMS), Rishikesh, India.

²Department of Surgery, All India Institute of Medical Sciences (AIIMS), Rishikesh, India.

³Department of Pathology, All India Institute of Medical Sciences (AIIMS), Rishikesh, India.

Authors' contributions

This work was carried out in collaboration among all authors. Authors AI and DS collected patient data. Authors SNR and JJ managed the literature searches. Authors SG and AG have written the manuscript. Author PJ did the pathological reporting. Author MG edited the manuscript. All authors read and approved the final manuscript.

Article Information

Editor(s):

(1) Dr. Lomas Kumar Tomar, Department of Pharmacology, Galway University Hospital, National University of Ireland, Galway, Ireland.

Reviewers:

(1) S. Danish Kadir, Rajshahi University, Bangladesh.

(2) Raghunadharao Digumarti, Homi Bhabha Cancer Hospital & Research Centre, India.

(3) Leonard Derkyi-Kwarteng, University of Cape Coast, Ghana.

Complete Peer review History: <http://www.sdiarticle4.com/review-history/54214>

Received 15 November 2019

Accepted 18 January 2020

Published 23 January 2020

Case Study

ABSTRACT

Gall bladder cancer carries a dismal prognosis especially in advanced cases. Common sites of metastases include liver, lung and unusual sites have also been reported like orbit, cutaneous, adrenal, kidney, breast and thyroid. 66 years female diagnosed case of metastatic carcinoma gall bladder presented with bilateral inguinal lymphadenopathy. Cytology aspirate from inguinal node reported metastatic adenocarcinoma. Inguinal node metastases from gall bladder cancer is very rare and few case reports have been published. We present a case of a woman with advanced cancer of the gall bladder, who presented with bilateral inguinal metastases.

Keywords: Gall bladder; inguinal node; metastases.

1. INTRODUCTION

Gallbladder carcinoma (GBC) is an aggressive disease and carries dismal prognosis, because of propensity to metastasize early to regional lymph nodes and adjacent liver parenchyma. Routes of spread comprise of vascular, lymphatic, intraperitoneal, neural and intraductal pathways. Lymphatic spread occurs in an extrapolative fashion and correlates with pattern of lymph node involvement in GBC. Inguinal node metastases in carcinoma of the gall bladder is uncommon and very few case reports have been published. Here, we present a case of GBC with metastasis to bilateral inguinal nodes.

2. CASE REPORT

A 66 years female presented with right upper abdominal pain for a month. It was dull aching, continuous, non radiating and was relieved with medication (non steroidal anti-inflammatory drugs). She had anorexia. There was no vomiting and fever. On clinical examination vitals were stable, a 3x 4 cm hard and non tender mass was palpable in right hypochondrium. A 2x 2.5 cm hard, mobile and non tender matted left supraclavicular node was palpable. Ultrasonography of the abdomen showed that the gall bladder wall was thickened, with multiple calculi; the liver was enlarged with a few periportal nodes. Contrast enhanced CT scan of thorax and abdomen showed asymmetric wall thickening of 13.2 mm of body and fundus gall bladder with periportal, pancreatic and paraaortic lymphadenopathy, largest measuring 1.4x1.9 cm. Serum CEA was 202 ng/ml and CA 19-9 was 4.5

U/ml. On the basis of clinicoradiological findings, diagnosis was metastatic carcinoma gall bladder, stage T2bN2M1 (IVB). A Fine needle cytology aspirate from Gall bladder mass was positive for malignant cells. Biopsy from left supraclavicular node was reported as metastatic deposits of mucinous adenocarcinoma. In view of her poor performance status, she was considered for palliative capecitabine based chemotherapy. She received two cycles of chemotherapy and then presented with bilateral lower limb edema. Examination showed diffuse bilateral lower limb edema, with calf tenderness. Bilateral inguinal nodes were enlarged largest measuring 1.5x 2 cm, hard and non tender. Contrast enhanced CT scan of thorax and abdomen reported gall bladder wall thickening 15 mm with loss of fat planes with duodenum, peripancreatic and periportal nodal mass largest, 2.4 x2.1 cm. Bilateral inguinal nodes were visualized 2x 1cm and 1.7x 1.2 cm on right and left side respectively (Fig. 1a &b). Fine needle aspiration cytology from bilateral inguinal nodes reported metastatic adenocarcinoma (Fig. 2a &b). Patient was considered for management of deep vein thrombosis and supportive care in view of poor general condition and progression of disease.

3. DISCUSSION

Gallbladder cancer (GBC) is the most common and aggressive malignancy of biliary tract and it is third common malignancy of gastrointestinal (GI) tract. It is more common in females. Adenocarcinoma is the most common histology. Less than 5% of patients with advanced GBC survive for 1 year [1]. Pattern of metastases

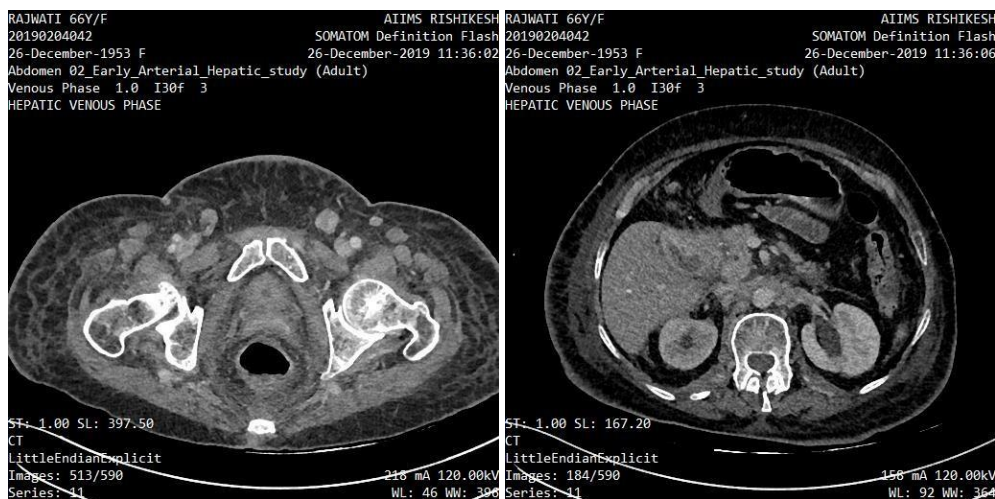


Fig. 1. Contrast enhanced CT scan of abdomen showing (a) bilateral inguinal nodes were visualized 2x 1cm and 1.7x 1.2 cm on right and left side (b) peripancreatic and periportal nodal mass largest, 2.4 x2.1 cm

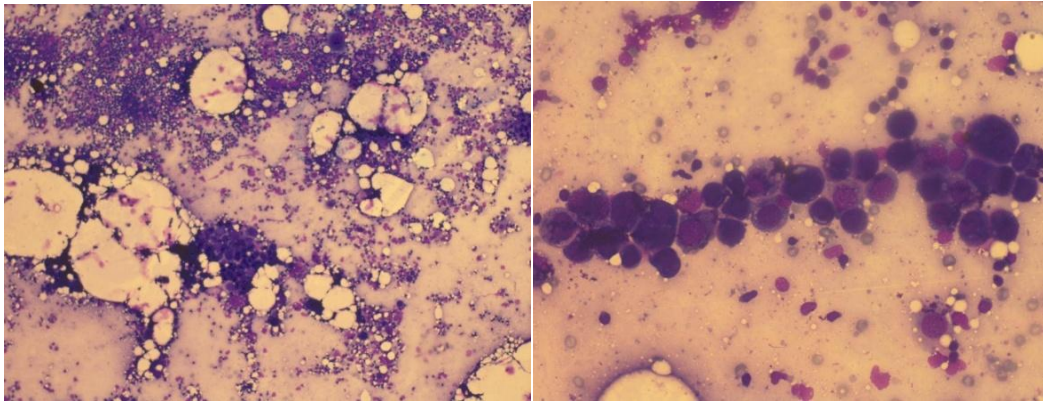


Fig. 2 (a&b). Cytology Aspirate from bilateral inguinal node are cellular and show singly scattered as well as small clusters of tumour cells with high nucleo cytoplasmic ratio, prominent nucleoli

include vascular, lymphatic, intraperitoneal, neural and intraductal pathways [2,3]. Most common organ involved is liver, by direct extension or metastasis followed by regional lymph nodes. Metastases from GBC occurs to organs liver, lymph nodes, adrenal, kidney, spleen, brain, breast, thyroid, heart and uterus. Involvement of skeletal system and cutaneous region are less common in GBC [4-8]. Pantola *et al.* and Shyam reported bilateral inguinal node metastases from carcinoma gall bladder [9,10]. There is a correlation between the lymphatic drainage of gallbladder and pattern of lymph node involvement in GBC. The three pathways as described by Ito *et al.* [11] are (1) cholecysto-retropancreatic pathway, (2) cholecysto-ceeliac pathway and (3) cholecysto-mesenteric route. Retrograde tumour spread is a known mechanism and lymphatic channel blockage by tumour cells leads flow of the lymph into retrograde fashion into some uncommon sites of metastases [12]. Likewise in our case also retrograde flow must have involved paraaortic nodes from where it might have spread to bilateral Inguinal nodes. Though metastasis to inguinal nodes in gallbladder carcinoma is rare, it may be an important characteristic of metastasis.

4. CONCLUSION

Gall bladder cancer carries a dismal prognosis especially in advanced cases. Most common sites of metastases include liver and lung. Inguinal lymph nodal metastases is rare in gastrointestinal malignancies. Presence of Inguinal node in carcinoma gall bladder should raise suspicion of metastases.

CONSENT AND ETHICAL APPROVAL

As per university standard guideline, participant consent and ethical approval have been collected and preserved by the authors.

COMPETING INTERESTS

Authors have declared that no competing interests exist.

REFERENCES

1. Gupta A, Gupta S, Chauhan U, Kumar U, Sharma N, Ahuja R, Rajput D, Gupta M. Symptom palliation in advanced gallbladder cancer: An institutional experience. *Indian J Palliat Care.* 2019;25: 514-16.
2. Hart J, Modan B, Hashomer T. Factors affecting survival of patients with gallbladder neoplasms. *Arch Intern Med.* 1972;129:931-934.
3. Piehler JM, Crichlow RW. Primary carcinoma of the gallbladder. *Surg Gynecol Obstet.* 1978;147:929-942.
4. Arminski TC. Primary carcinoma of the gallbladder; A collective review with the addition of 25 cases from the Grace Hospital, Detroit, Michigan. *Cancer.* 1949; 2:379-398.
5. Inoue T, Shiraki K, Fuke H, Yamanaka Y, Miyashita K, Ito K, Suzuki M, Sugimoto K, Murata K, Nakano T. Cardiac metastases of gallbladder carcinoma. *World J Gastroenterol.* 2005;11:2048-2049.

6. Misra S, Chaturvedi A, Misra NC. Carcinoma gallbladder presenting with skeletal metastases. Indian J Gastroenterol. 1997;16:74.
7. Puneet R, Kumar M, Khanna AK. Carcinoma gall bladder presenting as metastatic lung disease. Indian J Gastroenterol. 1999;18:44.
8. Sun KK, Shen XJ, Zhao H. An unusual case of cutaneous metastases from gallbladder cancer. Transl Cancer Res. 2017;6 (5):1005-1008.
9. Pantola C, Kala S , Singh PK, Khan L. Carcinoma Gall Bladder Presenting as Bilateral Inguinal Lymph node Metastasis. Journal of Case reports. 2012;2(2):72-75.
10. Shyam D. An Unusual Reach of Gallbladder Cancer: A Case Report. International Research Journal of Oncology. 2019;1(2):1-5.
11. Ito M, Mishima Y, Sato T. An anatomical study of the lymphatic drainage of the gallbladder. Surg Radiol Anat. 1991;13:89–104.
12. Dwivedi AD, Jain S, Dixit R. Gall bladder carcinoma: Aggressive malignancy with protean loco-regional and distant spread. World J Clin Cases. 2015;16;3(3):231-244.

© 2019 Ibrahim et al.; This is an Open Access article distributed under the terms of the Creative Commons Attribution License (<http://creativecommons.org/licenses/by/4.0>), which permits unrestricted use, distribution, and reproduction in any medium, provided the original work is properly cited.

Peer-review history:

*The peer review history for this paper can be accessed here:
<http://www.sdiarticle4.com/review-history/54214>*