

Short Communication

Oral cytology in human immunodeficiency virus (HIV): An immune marker?

Vaibhav Mahesh Jagad¹, Nandita Shenoy^{2*}, John Ramapuram³, Junaid Ahmed²,
Amitha Lewis⁴ and Srikant N.⁴

¹Manipal College of Dental Sciences, Mangalore Affiliated to Manipal University, India.

²Department of Oral Medicine and Radiology, Manipal College of Dental Sciences, Mangalore,
Affiliated to Manipal University, India.

³Department of General Medicine, Kasturba Medical College, Mangalore Affiliated to Manipal University, India

⁴Department of Oral Pathology, Manipal College of Dental Sciences, Mangalore Affiliated to Manipal University, India.

Received 21 July, 2013; Accepted 2 September, 2014

Low CD4 counts is currently considered to be one of the main indicators of the progression of human immunodeficiency virus (HIV)-induced immune depression, but few studies have analyzed its relationship to the presence of oral cytological changes. The aim of this cross sectional study was to analyze the relationship between total CD4 lymphocyte count and the occurrence of cytological changes. The present cross-sectional study included 40 HIV infected patients seen at a clinic for sexually transmitted diseases and HIV. Oral smears were obtained from dorsum of the tongue and the buccal mucosa using tongue blade and smear was transferred on a glass slide and fixed. The samples were assessed for the presence or absence of cytological changes, and correlated it with their CD4 counts. The CD4 lymphocyte counts of each of the 40 cases was noted and categorized as those below 500 cells/mm³ and above 500 cells/mm³. A total of 24 cases showed CD4 counts less than 500 cells. It was observed that the lesser the CD4 lymphocyte count, the greater the cell yield. These findings suggest that oral cytological changes could be a useful clinical marker of patients with HIV and can also be used as an adjuvant to CD4 counts. In view of these results, emphasis should be placed on the importance of thorough examination of the oral cavity and obtaining oral smears, as these changes provides indirect information about the patient's immune state.

Key words: Human immunodeficiency virus (HIV) infection, oral cytology, CD4 counts.

INTRODUCTION

Human immunodeficiency virus (HIV) infection is characterized by progressive and continuous impairment of the immune system function, with varying rate of progression among patients. Antiretroviral treatments (HAART) have been shown to be effective in arresting

immune system impairment and prevention of disease progression. The CD4 T-lymphocyte (CD4) count is considered the best laboratory marker of progression of HIV disease (Fahey et al., 1990). Many HIV-associated oral disorders occur early in HIV infection, not infrequently

*Corresponding author. E-mail: nandita.shenoy@gmail.com. Tel: +91-9901730507.

Author(s) agree that this article remain permanently open access under the terms of the [Creative Commons Attribution License 4.0 International License](http://creativecommons.org/licenses/by/4.0/)

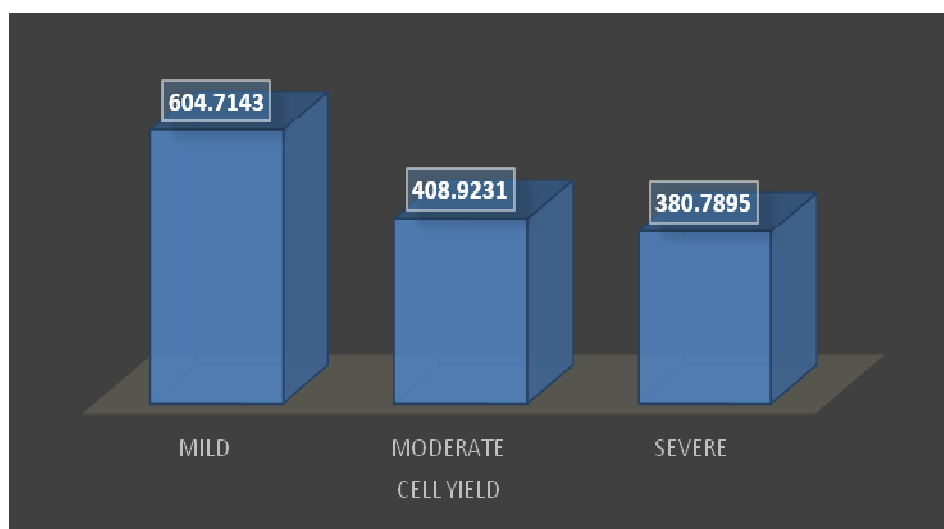


Figure 1. Comparison between cell yield and CD4 count.
P= 0.072; F= 2.832

infrequently as the presenting sign or symptom. Thus, early detection of associated oral disease should, in many cases, result in earlier diagnosis of HIV infection (Ranganathan et al., 2000). Cytology, a simple, painless and inexpensive method has become a preferred method for early diagnosis of certain lesions. HIV affects primarily the immune cells but there are studies (Montaner et al., 1992) which have concentrated on the cervical and gastrointestinal epithelium when investigating the various mechanisms of HIV infection across mucosal surfaces.

SUBJECTS AND METHODS

The present study included a group of forty HIV-infected patients seen at a clinic for HIV in Kasturba Medical College, Mangalore, India, for the diagnosis or follow up of this infection. All patients had been diagnosed with HIV infection by enzyme-linked immunosorbent assay (ELISA), and the diagnosis was confirmed by Western blot analysis. Informed consent was received from all patients. The patients seen at this clinic were first evaluated by physicians who specialized in HIV infection; these physicians determined from the patient's medical history if they met the criteria for inclusion in the study. The patients selected were referred to the laboratory, where they were examined following an established clinical and microbiological protocol. The clinical protocol consisted of a medical history, social history and general physical examination. The general examination included careful scrutiny of the oral cavity. Oral smears were collected from normal appearing tongue and buccal mucosa of 40 HIV infected (Study Subjects) and cells were analyzed for cell yield, cell cohesion, fungal growth and other atypical features. Oral cytological analyses of our subjects were compared with their CD4 counts. The cytological smears obtained from the HIV positive patients were evaluated based on factors like cell yield, cell cohesion, atypical features (increased nuclear cytoplasmic ratio and pleomorphism), presence of fungal organisms, bacterial colonies, the degree of inflammation and the type of inflammatory cells seen. The CD4 lymphocyte counts of

each of the 40 cases was noted and categorized as those below 500 cells/mm³ and above 500 cells/mm³.

Ethics committee

Ethical approval for the study was obtained from Institutional Ethics Committee of Manipal College of Dental Sciences, Mangalore. Informed consent was obtained from all study subjects before obtaining oral smears.

RESULTS

A total of 24 cases showed CD4 counts less than 500 cells. The CD4 lymphocyte counts were correlated with each of the cytological factors. It was observed that the lesser the CD4 lymphocyte count, the greater the cell yield (chi-square=4.393, p=0.111) (Figure 1). Cohesive clusters of cells were seen to be maximum in patients with CD4 counts less than 500 (chi-square=3.706, p=0.295). Increased nuclear cytoplasmic ratio was seen in 80% (n=12) cases with lower CD4 counts. On comparing the inflammatory component with CD4 lymphocyte counts, it was seen that the inflammatory cells were either cells were either absent or meagerly present and consisted mainly of acute inflammatory cells in HIV cases with CD4 counts less than 500 cells. Oral candida was commonly seen among subjects with lesser CD4 counts (Figure 2).

DISCUSSION

CD4+ T-lymphocyte counts are considered the markers for HIV disease progression, but not very affordable and

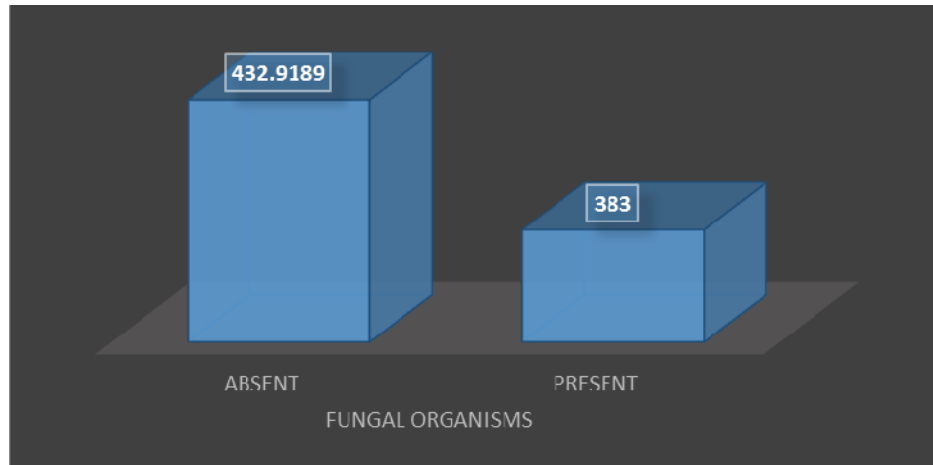


Figure 2. Comparison between oral Candida and CD4 count.
P= 0.776; T=0.3.

hence its use gets limited in developing countries. The use of total lymphocyte counts (TLC) has been advocated to predict and to stage HIV disease in some countries (Montaner et al., 1992; WHO, 1993). In this study, cost was not a limiting factor and CD4 counts are preferred to be used as a lab marker.

Our earlier study had revealed that HIV induces significant changes in oral epithelium, detectable by microscopy and cytomorphometry Jagad et al., 2014). In this study, a close association between the patient's immune state and the presence of cell yield were found with an increase in cell yield as CD4 lymphocyte counts decreased. In HIV-infected patients, oral candida (OC) was a frequent finding and has been associated with a less favorable immune status and more accelerated deterioration, similar findings were reported in other studies also (Dodd et al., 1991; Nielsen et al., 1994). Phelan et al. (1997) found that a CD4⁺ count of less than 200 or the presence of OC at the time of data collection increase the risk of death or development of AIDS, and such prognosis was much worse if both factors were pre-sent at the onset of evaluation. This relationship between OC, oral cytological alterations with reduced CD4 lymphocyte counts allows us to interpret these changes as an indirect marker of the immune status of HIV-infected patients when a CD4 count is unavailable (Burcham et al., 1991).

Some authors have recommended using the percentage of CD4 lymphocytes rather than CD4 counts, as the main indicator of immune function in HIV-infected patients, because the latter exhibited more variability in consecutive samples and had a poorer prognostic value for the development of AIDS (Malone et al., 1990).

Our results demonstrate that in patients with HIV, the degrees of immunosuppression determine the oral epithelial changes and a greater probability of presenting OC. Consequently, the presence of OC and other HIV-associated oral lesions could be clinical markers of the

disease progression defined by oral cytological changes and the latter may be a useful complementary indicator for monitoring antiretroviral therapy in HIV-infected patients.

Conclusion

Emphasis should be placed on the importance of cytological examination of the oral cavity in all medical follow-up examinations of HIV-infected patients, not only because of the need to diagnose and treat associated oral diseases, but also because the presence of these changes provides indirect information about the patient's immune state.

ACKNOWLEDGEMENT

The authors received no financial support for the research, authorship, and/or publication of this article.

Conflict of Interests

The authors declare no potential conflicts of interest with respect to the research, authorship, and/or publication of this article.

REFERENCES

- Burcham J, Marmor M, Dubin N (1991). CD4% is the best predictor of development of AIDS in a cohort of HIV-infected homosexual men. *AIDS* 5:365-72.
- Dodd CL, Greenspan D, Katz MH, Westenhouse JL, Feigal DW, Greenspan JS (1991). Oral candidiasis in HIV infection: pseudomembranous and erythematous candidiasis show similar rates of progression to AIDS. *AIDS* 5:1339-43.

- Fahey JL, Taylor JM, Detels R, Hofmann B, Melmed R, Nishanian P, Giorgi JV (1990). The prognostic value of cellular and serologic markers in infection with human immunodeficiency virus type-1. *N. Engl. J. Med.* 322:166-72.
- Jagad VM, Shenoy N, Ramapuram J, Lewis A, Srikant N, Sarin A (2014). Oral Cytology for HIV: A New Diagnostic Tool? *J. Int. Assoc. Provid. AIDS Care* 2325957414535256.
- Malone JL, Simms TE, Gray GC, Wagner KF, Burge JR, Burke DS (1990). Sources of variability in repeated T-helper lymphocytes counters from human immunodeficiency virus type 1-infected patients: total lymphocyte count fluctuations and diurnal cycle are important. *J. Acquir. Immune Defic. Syndr.* 3:144-51.
- Montaner JSG, Le TN, Le N, Craib KJP, Schechter MT (1992). Application of the World Health Organisation system for HIV infection in a cohort of homosexual men in developing a prognostically meaningful staging system. *AIDS* 6:719-24.
- Nielsen H, Bentsen KD, Højtvad L, Willemoes EH, Scheutz F, Schiødt M, Stoltze K, Pindborg JJ (1994). Oral candidiasis and immune status of HIV-infected patients. *J. Oral Pathol. Med.* 23:140-3.
- Phelan JA, Begg MD, Lamster IB, Gorman J, Mitchell-Lewis D, Bucklan RD, el-Sadr WM (1997). Oral candidiasis in HIV infection: predictive value and comparison of findings in injecting drug users and homosexual men. *J. Oral Pathol. Med.* 26(5):237-43.
- Ranganathan K, Reddy BV, Kumarasamy N, Solomon S, Vishwanathan R, Johnson NW (2000). Oral lesions and conditions associated with human immunodeficiency virus infection in 300 South Indian patients. *Oral Dis.* 6:152-7.
- WHO global programme on AIDS Proposed World Health Organisation staging system for HIV infection and disease (1993). *AIDS* 7:711-18.