



# Assessment of the Effect of *Vernonia amygdalina* and *Moringa oleifera* on Some Kidney Parameters in Alloxan–Induced Diabetic Rats

Nwahiri, J. D. <sup>a\*</sup>, Ozoemena, C. C. <sup>b</sup>, Okolonkwo, B. N. <sup>c</sup>,  
Nwosu, D. C. <sup>a</sup> and Nwanjo, H. U. <sup>a</sup>

<sup>a</sup> Department of Medical Laboratory Science, Imo State University, Owerri, Nigeria.

<sup>b</sup> Department of Medical Laboratory Science, Rivers State University, Port Harcourt, Nigeria.

<sup>c</sup> Department of Medical Laboratory Science, PAMO University of Medical Sciences, Port Harcourt, Nigeria.

## Authors' contributions

This work was carried out in collaboration among all authors. Authors NDC and NHU designed the work, while authors NJD, OCC and OBN carried out the analysis and literatures. All authors read and approved the final manuscript.

## Article Information

### Open Peer Review History:

This journal follows the Advanced Open Peer Review policy. Identity of the Reviewers, Editor(s) and additional Reviewers, peer review comments, different versions of the manuscript, comments of the editors, etc are available here:

<https://www.sdiarticle5.com/review-history/109513>

Original Research Article

Received: 24/09/2023

Accepted: 28/11/2023

Published: 02/12/2023

## ABSTRACT

**Aim:** The study aims to assess the effect of *Vernonia amygdalina* on some kidney function parameters in Alloxan – induced diabetic rats.

**Study Design:** Experimental study.

**Place and Duration of Study:** The study was conducted at the Departments of Biochemistry and Histology, Imo State University, Owerri, Nigeria, between September 2014 and September 2016.

**Methodology:** Thirty (30) rats with body weights ranging from 180 to 200 grams were split into five groups, each with six rats. As the control group, Group 1 was fed a regular diet. Group 2, which

\*Corresponding author: E-mail: judenwal777@gmail.com;

consists of diabetics, was not given plant extract treatment and instead received Alloxan (150 mg/kg body weight). Group 3 was administered Alloxan and was given a single plant extract (VA). Group 4 was administered Alloxan and was given a single plant extract (MO). Alloxan was administered to Group 5 along with a combination of VA and MO plant extracts. After 28 days of treatment, serum urea, creatinine and kidney histology were examined.

**Results:** In group 3, the amounts of urea and creatinine were lowered by the VA plant extract. In group 4, the MO also decreased the levels of urea, and creatinine. When compared to the diabetic group, the combination therapy of aqueous plant extracts of VA and MO significantly decreased the levels of urea, and creatinine in group 5. Histological examinations supporting the results showed considerable reduction and amelioration of the abnormalities in the Alloxan + VA, Alloxan + MO, and Alloxan + VA + MO groups, and marked distortions and degenerations of renal tissues in the diabetic group.

**Conclusion:** The combination use of plant extracts from VA and MO demonstrated synergistic effects on diabetic renal tissues and this finding could provide a baseline for other related research studies.

**Keywords:** *Vernonia amygdalina* and *Moringa oleifera*; kidney parameters; alloxan – induced diabetic rats.

## 1. INTRODUCTION

Cardiovascular diseases, retinopathy, and nephropathy are among the chronic complications linked to diabetes mellitus (DM) [1]. The enzyme glucokinase (GK), the beta cell glucose sensor, plays a crucial role in maintaining glucose homeostasis by phosphorylating and controlling glucose metabolism in hepatocytes and beta-cells [2].

It has been demonstrated that treating hyperglycemia with insulin can prevent hypertrophy, hyperfiltration, and the ensuing increase in urine protein excretion. The most significant nitrogen constituents of blood serum are amino acids, urea, creatinine, uric acid, and ammonia; these constituents have consequences for clinical biochemistry. Due to low serum levels and a lack of energy derived from carbohydrates, protein catabolism increases in diabetes mellitus. Male diabetic rats had elevated serum urea, uric acid, creatinine, and electrolyte levels; ginseng supplementation significantly enhances renal function and reverses these abnormalities in diabetic rats [3]. Alloxan-induced diabetes mellitus causes histological alterations in the kidney, liver, and pancreas. The most effective pathophysiology in the pancreas is the loss of  $\beta$ -cell mass, which destroys  $\beta$ -cells and prevents the production of insulin, which results in IDDM. The primary cause of beta-cell death in the pancreas is apoptosis, and these cells are the target of autoimmune attacks. Exposure to soluble cytokines and reactive oxygen species (ROS) or direct contact with activated T-cells and

macrophages can cause  $\beta$ -cell apoptosis. NIDDM is distinguished not only by alterations in pancreatic histology but also by a confluence of insulin resistance and  $\beta$ -cell dysfunction.

The primary organ of the human excretory system, the kidneys eliminate waste products from metabolism to maintain homeostasis. Diffuse mesangial sclerosis, nodular glomerulosclerosis, and thickening of the capillary basement membrane are the three most significant glomerular lesions observed in IDDM. Although there are lesions in the surrounding tissue and tubular structures, the glomerular capillary basement membranes are thickened throughout. Together with early progressive nephron damage, there may also be a reduction in the survival of the podocytes that surround the glomerular capillaries [4]. Over the course of several years, the disease progresses at each patient's unique rate, but eventually the majority of the glomeruli will be destroyed, leaving the patients with inadequate filtration capacity. *Verona amygdalina* is a medicinal plant of Asteraceae family and has a vast importance concentrating majorly on medicinal aspect. However, the plant is also useful in ecology as it helps in the beautification and purification of the environment by releasing oxygen during photosynthesis. *V. amygdalina* can also be used as food supplements when prepared with Melon (egusi soup) a nutritious African food.

An estimated 815 million people in developing countries suffer from malnutrition, and infants and children are the worst hit. Unfortunately, efforts at improving food production and

accessibility in these regions have been directed lopsidedly to roots/tubers, cereals, and animal production. The largely ignored dark green leafy vegetables can however augment the nutrients derivable from other sources, thereby reducing malnutrition tremendously.

All plant parts of *Moringa oleifera* are traditionally used for different purposes, but leaves are generally the most used [5]. They are used in human and animal nutrition and in the traditional medicine. Leaves are rich in protein, mineral, beta-carotene, and antioxidant compounds, which are often lacking among the populations of underdeveloped or developing countries. *Moringa* leaves are added to food preparations as integrators of the diet. In traditional medicine, these leaves are used to treat several ailments including malaria, typhoid fever, parasitic diseases, arthritis, swellings, cuts, diseases of the skin, genito-urinary ailments, hypertension, and diabetes. They are also used to elicit lactation and boost the immune system (to treat HIV/AIDS related symptoms, as well as cardiac stimulants and contraceptive remedy. One can directly consume either raw and dried leaves or the extract of an aqueous infusion. The aim of this study was to assess the effect of *Vernonia amygdalina* and *Moringa oleifera* on some kidney function parameters in Alloxan – induced diabetic rats.

## 2. MATERIALS AND METHODS

### 2.1 Plant Materials

Freshly matured leaves of *Moringa oleifera* (MO) and *Vernonia amygdalina* (VA) were collected from the Owerri metropolis' neighborhood compound. After giving the leaves multiple rinses with fresh tap water to get rid of any dust or debris, they were allowed to air dry entirely. Dr. Mbagwu V. of Imo State University's Department of Plant Science and Biotechnology in Owerri identified the plants.

#### 2.1.1 Preparation of plant extract

Separately, the leaves of MO and VA were ground into a powder. To fully extract the active ingredients from the plant, 100 grams of each powdered leaf was dissolved in one liter of warm distilled water and refrigerated at 4°C for 48 hours. To create a homogenous filtrate, these were first filtered through a cheese cloth and then again through Whatman No. 1 filter paper. Following the filtering process, the concentrates

were allowed to open in a water bath at 40°C to ensure total dryness. *Vernonia amygdalina* and *Moringa oleifera* material was found and preserved independently. It was greenish brown in color.

### 2.2 Experimental Animals

For this study, thirty adult male albino rats weighing between 180 and 200 g were obtained from the Anatomy department at Imo State University in Owerri, Nigeria. The rats were housed in standard cages with 12 light/dark cycles, controlled for temperature and relative humidity.

#### 2.2.1 Experimental induction of diabetes

Diabetes was induced in twenty - four overnight fasted rats by a single intraperitoneal injection of Alloxan (Sigma - Aldrich ST. Louis, USA) at a standard dose of 150mg per kilogram body weight, dissolved in 0.85 g per 100ml normal saline solution. The Animals were confirmed diabetic if the glucose level of blood of fasted animals, collected from tail vein after 48hours of injection of Alloxan was above 120mg/dl (7.0mmol/l) as determined with an automated glucose analyzer device (One touch glucometer, Acon Laboratories Inc, USA).

### 2.3 Experimental Design

Thirty rats were divided into five experimental groups of six rats each:

Group 1: formed the normal control group (NC) and were fed with rat diet and water only.

Group 2: formed the positive control group - diabetic group not treated with plant extracts. They were induced with diabetes using Alloxan and fed with rat diet and water.

Group 3: rats were induced diabetic rats and treated with only *Vernonia amygdalina* (VA) extract at a standard dose of 200mg per kilogram body weight.

Group 4: were induced diabetic rats and treated with *Moringa oleifera* (MO) extract at a standard dose of 200mg /kg body weight.

Group 5: were induced diabetic rats and treated with combined plant extracts of *Vernonia amygdalina* and *Moringa oleifera* at a standard dose of 200mg/kg body weight of the rats.

The two plant extracts, reconstituted in distilled water were administered orally through gastric intubation, at a standard dose of 200mg per kilogram body weight for a single extract treatment, and 400mg per kilogram body weight for combined extracts treatment, the optimal dose. The duration of treatment was 28 days after induction of diabetes. At the end of the experimental periods, the rats were fasted for 12 hours, then anaesthetized under chloroform vapour and sacrificed. Whole blood was obtained by cardiac puncture into sterile plain tubes and allowed to clot for thereafter centrifuged to remove the cells. Serum removed was used for the biochemical assays. The kidneys were surgically removed for histological studies.

## 2.4 Laboratory Analysis

All reagents were purchased, and manufacturer's standard operational procedure (SOP) strictly adhered to.

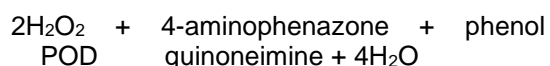
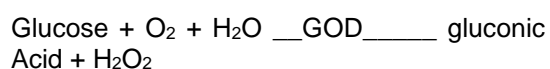
### 2.4.1 Determination of glucose (Randox Kit Catlog No\_\_ GL 364)

#### 2.4.1.1 Method

Glucose Oxidase Method was used to assay for blood glucose levels in the samples, to ensure the rats were diabetic.

#### 2.4.1.2 Principle

Glucose is determined after enzymatic oxidation in the presence of glucose oxidase. The hydrogen peroxide formed, reacts under catalysis of peroxidase, with phenol and 4-aminophenazone to form a red violet quinoneimine dye as indicator.



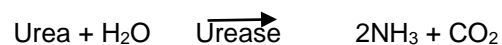
### 2.4.2 Determination of Urea (Randox Kit Catlog No—UR 1068)

#### 2.4.2.1 Method

The method used for the analysis of serum urea is urease method.

#### 2.4.2.2 Principle

Urea in serum is hydrolysed to ammonium in the presence of Urease. The ammonia is then measured photometrically by Berthelot's reaction.



$\text{NH}_3$  + Hypochlorite + Phenol Indophenol (blue colour)

### 2.4.3 Determination of Creatinine (Randox Kit Catalog No --- 510)

#### 2.4.3.1 Method

The method used was picric acid method.

#### 2.4.3.2 Principle

Creatinine in alkaline solution reacts with picric acid to form a colored complex. The amount of the complex is directly proportional to the creatinine concentration.

## 2.5 Statistical Analysis

Results were analyzed using SPSS 16. All data were reported as mean  $\pm$  SD and test of significance was done using one-way ANOVA with 95% confidence limit.

## 3. RESULTS AND DISCUSSION

The mean  $\pm$  SD of values of glucose ( $13.7 \pm 0.88\text{mmol/l}$ ) of rats not treated with plant extract after diabetes induction by Alloxan were significantly increased ( $p < 0.05$ ) when compared with the normal control group ( $4.3 \pm 0.49\text{mmol/l}$ ). This is probably due to the devastating effect of alloxan on the pancreatic islet cells, by destroying the insulin-secreting cells of the Islet of Langerhans. This report agrees with Kaneto et al. [6], who, in his report attributed such pathological changes to glucotoxicity, which arises from excessive up take of glucose by islet beta cells in diabetes.

In the current research work, the mean  $\pm$  SD values of Urea ( $15.8 \pm 0.89\text{mmol/l}$ ) and Creatinine ( $131.3 \pm 2.43 \text{ mmol/l}$ ) of rats not treated with plant extract after diabetes induction by Alloxan were increased when compared with the normal control group, Urea ( $3.5 \pm 9.90 \text{ mmol/l}$ ) and Creatinine ( $49.9 \pm 6.89 \text{ mmol/l}$ ). This could be attributed to chronic renal failure resulting from diabetic nephropathy as one of the

complications of diabetes. These findings tallied with Cheesbrough, [7] in her work on renal function. He reported that a marked and prolonged increases in serum or plasma Urea and Creatinine levels were indicative of impaired renal failure. These findings agreed with Atangwho et al. [8] who reported that plant extract of VA was proved to reduce Urea and Creatinine levels in the serum of the rats. In the present study, the mean  $\pm$  SD values of Urea ( $6.4 \pm 1.14$  mmol/l), Creatinine ( $74.6 \pm 7.23$  mmol/l) and glucose ( $7.9 \pm 0.78$ ) of rats treated with combined plant extracts of *Vernonia amygdalina* and *Moringa oleifera* (VA +MO) after diabetes induction by Alloxan were much more reduced when compared with the diabetic group. This could be attributed to the synergistic potential of the combined plant extracts of VA and MO on the kidney and glucose levels of Alloxan induced diabetic rats.

In the present study, the photomicrograph of the section of the kidney from the control group (Plate 1) showed an intact and normal endothelium, urinary space, renal tubules, and connective tissues. In the diabetic group (Plate

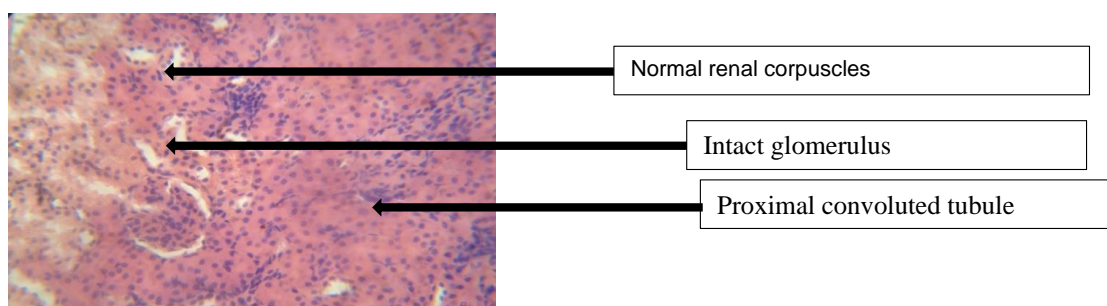
2), the histological examinations showed a marked distortions and degenerations of the kidney tissues. This could be because of diabetic disorders and complications induced by Alloxan. However, there were reduced distortions and degenerations of the kidney tissues and cells in the Alloxan and VA group (Plate 3). This could be attributed to the ameliorative effect of VA plant extract on the Kidney tissues. There were also decreased distortions and degenerations of the Kidney tissues in Alloxan and MO group (Plate 4). This could be attributed to the ameliorative and protective effects of MO plant extract on the Kidney tissues. This agreed with Kakey et al. [9].

There was much more reduction in the distortions and degenerations of the kidney tissues in Alloxan, VA and MO group when compared with the diabetic group (Plate 5). This could be attributed to great synergy provided by the combined therapy of the two plant extracts (VA and MO) that resulted in the amelioration and protection of the kidney tissues. These findings were in line with the reports of Kakey et al. [9], Babalola [10] and Atangwho et al. [11].

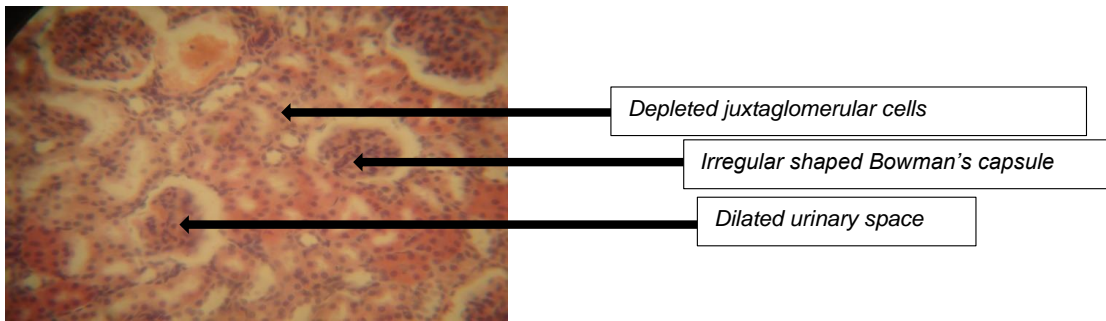
**Table 1. Comparisons of urea and creatinine values for all groups**

Parameter/Group	Urea (mmol/l)	Creatinine (mmol/l)
Group 1 (N=6)	$3.367 \pm 0.665$	$50.68 \pm 7.272^2$
Group 2 (N=6)	$16.22 \pm 1.034$	$130.9 \pm 1.613^{3,4,5}$
Group 3 (N=6)	$9.067 \pm 0.686$	$82.28 \pm 7.682$
Group 4 (N=6)	$21.50 \pm 32.09$	$84.68 \pm 8.096$
Group 5 (N=6)	$6.533 \pm 1.232$	$75.70 \pm 7.536$
F-value	1.588	106.8
P-value	0.2084	<0.0001
Remark	NS	S


Key: S – significant (ANOVA), 2,3,4,5 significant compared to the number of group




**Plate 1.** This represents the photomicrograph of the section of the Kidney of diabetic rats of the normal control group. The section shows the renal cortex of the Kidney. The glomerulus presented with good endothelium. The renal / urinary space is adequate. The parietal and visceral layers of the Bowmans capsule were intact. The juxta glomerular apparatus was also intact. The renal tubule, linings, connective tissues, and blood vessels were all intact



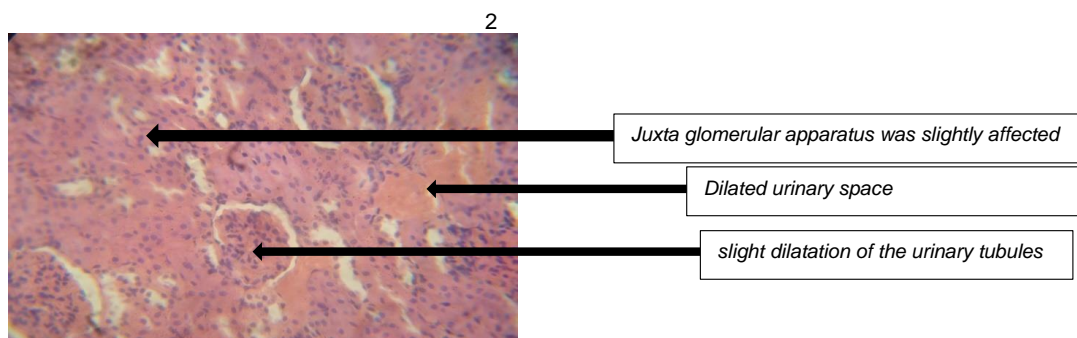
**Plate 2.** Photomicrograph of the section of the renal cortex of diabetic rats not treated with any plant extract. The section of the cortex shows a glomerulus with intact endothelium but with most dilated urinary space. The capsular layers were desquamated with gross cellular depletion of the urinary tubules and the connective tissues. The juxta glomerular cells were also depleted, and sclerotic activities noticed



**Plate 3.** This represents the photomicrograph of the section of the renal cortex of diabetic rats treated with only Vernonia amygdalina plant extract. The section shows the renal cortex whose glomeruli have well demonstrated endothelium but dilated urinary space. The epithelium lining of the capsular layers were intact. Juxta glomerular apparatus was slightly affected



**Plate 4.** Photomicrograph of the section of the Kidney of diabetic rats treated with only Moringa oleifera. The section shows renal cortex whose glomeruli have well demonstrated endothelium with dilated urinary space. Juxtaglomerular apparatus was moderately distorted. The epithelium lining of the capillary layers were intact



**Plate 5. Photomicrograph of the renal cortex of diabetic rats treated with combined plant extracts of Vernonia amygdalina and Moringa oleifera. The section shows the cortex of the Kidney whose glomeruli presented with good endothelium for ultra filtration. The urinary space was wide with slight dilatation of the urinary tubules. Juxta glomerular apparatus was also intact. Sclerotic condition of the arteries was slightly noticed**

#### 4. CONCLUSION

Rats' blood urea and creatinine levels rose in response to alloxan, while those of VA and MO decreased. The combined use of plant extracts from VA and MO had synergistic effects on diabetic renal tissues and offered a less expensive treatment option for diabetic kidney diseases.

#### CONSENT

It is not applicable.

#### ETHICAL APPROVAL

All authors hereby declare that Principles of laboratory animal care (NIH publication No. 85-23, revised 1985) were followed, as well as specific national laws where applicable. All experiments have been examined and approved by the appropriate ethics committee (Ethical committee of Imo State University, Owerri, Nigeria).

#### ACKNOWLEDGEMENTS

Authors are grateful to Mr Festus Emegaha for assisting in the preparation of the seed extract and feeding the animals, Mr Chinedu for sample collection, Mr Samuel for assisting in slide preparation and Dr. Rexclovis for statistical analysis.

#### COMPETING INTERESTS

Authors have declared that no competing interests exist.

#### REFERENCES

1. Mahdi AA, Chandra A. Sigh RK, Shukla S, Mishra LC. Effect of herbal hypoglycemic agents on oxidative stress and anti-oxidant status in diabetic rats. Indian J. Chin. Biochan. 2003;18:8-14.
2. Lypedjian PB, Pilot PR, Nouspikel T, Milburn JL, Quaade C, Hughes S, Ucla C, Newgard CB. Proc. Natl. Acad. Sci. U.S.A. 1989;86:7838-42.
3. Sawiress FAR. Effect of Ginseng extract supplementation on Renal functions in diabetic Rats. J. Agric Sci. 2011;3(2):17-31.
4. Wolf g, chen S, Ziyadeh FN. From the periphery of the glomerular capillary wall toward the centre of disease: Podocytes injury comes of age in diabetics nephropathy. Diabetes. 2005; 54: 1626–34.
5. Popoola JO, Obembe OO. Local knowledge, use pattern and geographical distribution of Moringa oleifera Lam. (Moringaceae) in Nigeria. J. Ethnopharmacol. 2013;150:682–91.
6. Kaneto H, katakami N, kawamori D, Mijatsuka T, Sakamoto K, Mat-Suko TA, Involvement of Oxidative stress in the pathogenesis of diabetes. Antioxid Redox signal. 1991;9:355- 66.
7. Cheesbrough, M. District Laboratory practice in tropical Countries, part 1. Cambridge University press. 2007; 358–61.
8. Atangwho IJ, Ebong PE, Egbuna GE, Eteng M.U. Effect of Vernonia amygdalina on Liver function in alloxan-induced

- hyperglycaemic rats. Journal of pharmacy and bio resources. 2007;4:110-2. Accessed on: Jan., 2007;13.
9. Kakey, Ismial S, Sarmad R, Kareem and Kamal Ahmad. Role of green tea extract in the improvement of Liver and renal functions in Alloxan induced diabetes mellitus in male albino rats. International Journal of Medicine and Medical Science Research, 2014;2(3):024-38.
  10. Babalola OO, Anetor JI, Adeniyi FA. Amelioration of carbon tetrachloride-induced hepatotoxicity from leaves of Vernonia amygdalina. Afri J Med Sci. 2001;30:91-3.
  11. Atangwho IJ, Ebong PE, Egbuna GE, Eteng MU, Eyong EU, Obi AU. Effect of Vernonia amygdalina leaf on kidney function of diabetic rats. Int J. Pharmacol. 2007;3:143-8.

---

© 2023 Nwahiri et al.; This is an Open Access article distributed under the terms of the Creative Commons Attribution License (<http://creativecommons.org/licenses/by/4.0>), which permits unrestricted use, distribution, and reproduction in any medium, provided the original work is properly cited.

*Peer-review history:*

*The peer review history for this paper can be accessed here:*  
<https://www.sdiarticle5.com/review-history/109513>