

# The Root Causes of Lumbar Canal Stenosis: An Insight with a Narrative Review

ANKIT JAISWAL<sup>1</sup>, RAMEEZ BUKHARI<sup>2</sup>, PRATEEK UPADHYAY<sup>3</sup>

## ABSTRACT

In the older population, lumbar spinal stenosis is a frequent degenerative condition that can cause clinical symptoms such as neurogenic claudication or sciatica, either with or without low back pain. Anatomically, there are three different forms of lumbar spinal stenosis: central, foraminal, and lateral recess. The relationship between Ligamentum Flavum (LF) hypertrophy and mechanical stress, as seen in segmental instability or disc space expansion, and their correlation with lumbar facet joint arthropathy is still not clear. This review places particular emphasis on the causes like LF hypertrophy, lumbar segmental instability, lumbar segmental motion, disc degeneration, lumbar spine facet joint orientation, facet joint tropism and facet joint Osteoarthritis (OA) in Lumbar Canal Stenosis (LCS) studied in various different studies discovered in various other search databases. The present research will also help surgeons and radiologists to interpret neuroradiological data appropriately for surgery as well as non surgical treatment and get a better knowledge of the architecture of these structures and how they appear on neuroimaging investigations for further proper and apt management of LCS. Additionally, it would assist in creating a diagnostic algorithm for better functional results.

**Keywords:** Claudication, Degeneration, Imaging, Lumbar

## INTRODUCTION

Spinal stenosis is the common term for the constriction of one or more foramina (bony apertures) within the spine. Depending on the precise location(s) where the narrowing and nerve compression occur, there are several labels for spinal stenosis. The highest incidence of LCS was seen in the age group of 31 to 40 years (36.7%). It is estimated that 5-60% of the stenosis cases may involve atleast more than and equal to two level of the spine i.e., cervical and lumbar regions (Tandem stenosis). Anatomically, there are three different forms of lumbar spinal stenosis: central, foraminal, and lateral recess [1].

### 1. Central Canal Stenosis

The bony aperture in the middle of the vertebra known as the vertebral foramen serves as protection for the spinal cord as it passes through the spinal canal. Central canal stenosis is the medical term for when one or more of these vertebral foramina are narrowed. As the spinal cord may become compressed due to central canal stenosis, any part of the body below the degree of compression may feel discomfort or malfunction. Although central canal stenosis can happen anywhere along the spine's vertebral foramina, it usually happens in the lumbar or cervical spine. Moreover, foraminal and central canal stenosis can both happen simultaneously [1].

### 2. Foraminal Stenosis

The intervertebral foramen is the bony opening where spinal nerve exits the spinal canal between two adjacent vertebra. Whenever one or more foramina narrows, it is known as foraminal stenosis. Spinal nerves branches of the cord can be compressed on right or left-side and into the body. In this, spinal nerve becomes pinched and leads to radicular pain and/or dysfunction. Its usually seen in lumbar spine. This is the most common form of spinal stenosis [1].

### 3. Lateral Recess Stenosis

When the nerve is compressed just before it reaches the intervertebral foramen it is known as lateral recess stenosis. If spinal nerve has compressed after exiting from foramina, it is known as far lateral stenosis [1]. Herniation of the intervertebral disc, hyperplasia of the articular process and hypertrophy of the LF are the typical causes of lateral recess stenosis. Despite the fact that clinical symptoms

might vary, this progressive condition results in chronic pain and functional impairment, limiting mobility as well as the capacity to carry out activities of daily living [2]. The most often implicated levels in degenerative lumbar disease with lateral lumbar spinal stenosis in the elderly are L4-L5, L5-S1 [3].

The highest incidence of LCS was seen in the age group of 31 to 40 years (36.7%). Incidence reduces over 60 years and none was seen below the age of 20 years [4]. Pathogenesis of Lumbar Spinal Canal Stenosis (LSCS) is significantly influenced by posterior spinal structures, particularly the LF thickness [5].

## ✦ POTENTIAL FACTORS LEADING TO LUMBAR CANAL STENOSIS (LCS)

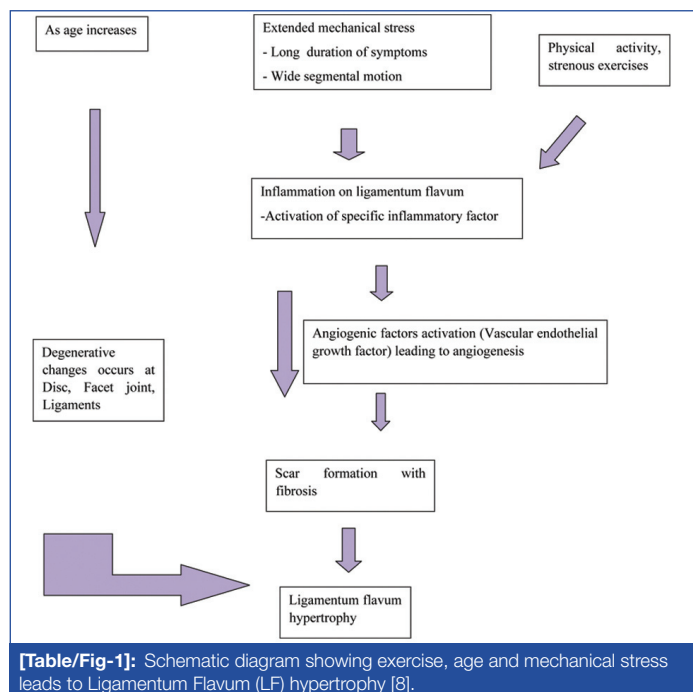
### a) Ligamentum Flavum (LF) Hypertrophy

The LF, also referred to as the yellow ligament, runs from the second cervical to the first sacral vertebra [5]. It starts from the anterior surface of the lower portion of the lamina above and inserts into the posterior surface and superior border of the lamina below. It reaches from the facet joint capsules laterally to the location where the laminae medially unite to produce the spinous process. It joins the laminae of the neighbouring vertebrae in the spinal column with its superficial and deep components, preventing the laminae from separating during spinal flexion and restoring erect posture following flexion [4].

The LF is a connective tissue that is thought to affect the intrinsic stability of the spine, intervertebral movement control and maintenance of a smooth surface of the posterior dural sac. Its precise function is unknown. The LF lines a significant portion of the osseous and soft tissue portions of the posterior epidural area and joins two neighbouring laminae [6]. Since LF thickening (hypertrophy) might decrease spinal canal width, it has been hypothesised that LF thickness contributes to LSCS [7]. As people age, their collagen fibres will grow and their elastic fibres will shrink, decreasing the ligament's elasticity [7,8].

A number of factors, including exercise level, age and mechanical stress, contribute to LF hypertrophy [Table/Fig-1] [8]. The development of lumbar spinal stenosis, or compression of the dural sac and roots, is thought to be caused in part by LF hypertrophy, which also significantly contributes to low back pain and sciatica

[8]. The nerve root or cauda equine is mechanically compressed by canal narrowing and causes sciatica and lower back pain even when there are no osseous spurs, a herniated nucleus pulposus, or a bulging annulus fibrosus [6,8].



### b) Asymmetry of Facets (TROPISM)

Facet tropism was first described by Brailsford JF in 1928 as an asymmetry in the angles of the left and right vertebral facet joints, with one joint exhibiting a more sagittal orientation than the other [9]. The association between facet tropism and the development of lumbar disc herniation was initially proposed by Farfan H and Sullivan J [10].

Angle is calculated in the axial planes, with angle assessed between lines along the posterior border of the vertebral body and another line bisecting the superior and inferior tips of the facet joint process [10]. The angle difference between the bilateral faces needs to be determined. Tropism is identified when there is an angulation difference of 8° or more between the facet joints [11].

Asymmetry in the lumbar and lumbosacral facet (apophyseal) joint angles is known as tropism. One joint has greater coronal orientation as a result than the other. It has been hypothesised that this might result in disc disease because tropism causes the spinal motion segment to rotate abnormally, increasing the torsional stress on the intervertebral disc. Additionally, it has been proposed that the angle of the facet joint itself plays a crucial role in safeguarding the disc and those who have more obliquity in their facets are more likely to develop disc disease [10].

According to Weishaupt D et al., there is moderate to good agreement between Magnetic Resonance Imaging (MRI) and Computerised Tomography (CT) when it comes to OA of the lumbar facet joints [12]. Agreement is even great when minor variances are taken into account. Therefore, a CT scan is not necessary to evaluate facet joint degeneration when an MR examination is available.

### c) Disc Degeneration, Disc Space Widening and Angulation of Disc Space

Disc has tough outer wall known as annulus and inside it is filled with gel called as nucleus. It is present between the vertebra and acts as shock absorbing that prevent the bones from rubbing together. Degenerated disc disease can occur in any region of spine, most common in lumbar region in which disc lost their flexibility and height [12]. The overgrowth of ligament and joint causes the spinal canal to narrow which can compress the spinal cord and nerves causing spinal stenosis [13]. Due to damage to anterior longitudinal

ligament, there is disc space widening and angulation of disc space due to axial load may occur [7].

### d) Facet Joint Arthrosis

Facet joint arthrosis is a common radiographic finding and has been suggested as a cause of low back and lower extremity pain. It is regarded as a basic component of the three-joint complex model and is considered a dominant player in the genesis of lumbar spinal stenosis. The zygapophyseal joints are the only synovial joints in the spine with hyaline cartilage overlying subchondral bone, a synovial membrane, and a joint capsule [13]. Conventional radiography (X-rays films) still remains the most common screening method for evaluating these changes. It is well accepted that facet joints arthrosis is an age-dependent phenomenon but can be associated with sex. The L5-S1 segment withstands the highest compressive loading and depicts the greatest lordosis, which causes the highest shear forces [12].

### e) Vacuum Phenomenon

Vacuum phenomenon is a collection of gases in the intervertebral space, principally nitrogen gas and there is displacement of gas posteriorly within the epidural space leading to compression of spinal cord but it's rare as compared to other causes [7,14].

Clinical and anatomical studies discuss the surgical repercussions of LF hypertrophy as a cause of low back pain [14]. The LF's normal architecture, hypertrophy, calcification, ossification, and amyloidosis have all been covered in other papers [7].

According to a review by Genevay S et al., researchers developed inclusion criteria for studies in patients with lumbar spinal stenosis using a range of symptoms, clinical indications, and radiological criteria [15]. Imprecise nomenclature restricts the clinical relevance and interpretability of study results.

To prevent spinal instability, it is essential that 50% of the facet joint be retained after surgical decompression [16]. Even when bilateral laminectomies were conducted, there was a relatively high frequency of insufficient lateral stenosis decompression, which led to the continuation of neurological symptoms after surgery [16].

## ✦ EVALUATION OF PARAMETERS CAUSING LUMBAR CANAL STENOSIS (LCS)

### 1. Measurement of Ligamentum-flavum Thickness

Maximum allowable LF thickness has been defined as <4 mm [17]. Moreover, the vast majority of studies utilised flavum tissue from cadavers or even during surgery. Flavum specimens that were cut off from their attachments have a tendency to compress and buckle which affects their thickness and poses a concern [17]. The broad array in flavum thickness mentioned in the literature results from the various measuring techniques employed, the demographic nature of the populations under study, as well as the subject's health background [Table/Fig-2] [8,18-27].

The mean LF thickness increased caudally from L1-L2 to L5-S1 level, being thickest at L5-S1 level. Tukeys test showed that the LF thickness at L5-S1 was significantly high ( $p < 0.0001$ ) which is in concordance with the study by Ramani PS et al., Fukuyama S et al., and Spurling RG et al., and Sudhir G et al., [22,23,25,27]. They had observed LF thickness values as high as 6.13 mm in their studies and according to Kolte VS et al., the fact that their research was carried out on elderly patients may have contributed to the higher results found in the studies [17].

Although based on the findings, the L5-S1 level had a mean LF thickness that was greater than the L4-5 level, L4-5 had the highest incidence of LF hypertrophy ( $\geq 4$  mm) which were in congruence with the findings of the study conducted by Sudhir G et al., [27].

• **Asymmetry of Ligamentum Flavum (LF) Thickness:** It was observed that left LF at the L4-L5 and L5-S1 levels was significantly

Study	Population	Measuring technique	Level	LF thickness (mm)
Park JB et al., 2001 [18]	Living herniated disc (n=10)	MRI	Lumbar spine	2.44 and 4.44
Yong-Hing K et al 1976 [8]	Specimens (n=107)	Caliper	Lumbar spine	2-3
Ramsey RH et al., 1976 [19]	Cadaver (n=12)	Caliper	Lumbar spine	4-6
Brown HA et al., 1938 [20]	Specimens (n=7)	Caliper	Lumbar spine	2-3
Horwitz T et al., 1939 [21]	Cadavers (n=21)	Caliper	L3-L4	3.5
			L4-L5	3.8
Ramani PS et al., 1975 [22]	Cadavers (n=18)	Caliper	L4-L5	6.13
			L5-S1	5.2
Fukuyama S et al., 1995 [23]	Living non degenerative (n=51)	CT	L3-L4	2.9
			L4-L5	3.1
			L5-S1	3.4
Sairyo K et al., 2005 [24]	Living LBP (n=77)	MRI	L3-L4	3.25
			L4-L5	4.08
			L5-S1	2.68
Spurling RG et al., 1937 [25]	Cadavers (n=40)	Caliper	L3-L4	4.3
			L4-L5	4.4
Yoshiiwa T et al., 2016 [26]	Living LBP (n=419)	CT MRI	L4-L5	4.4±1.0
Sudhir G et al., 2019 [27]	Living LBP (n=214)	MRI	Right	Right
			L1-L2	3.25±1.13
			L2-L3	3.33±1.11
			L3-L4	3.75±1.18
			L4-L5	4.54±1.36
			L5-S1	4.80±1.30
			Left	Left
			L1-L2	3.06±1.12
			L2-L3	3.32±1.05
			L3-L4	3.58±1.18
			L4-L5	4.17±1.47
			L5-S1	4.42±1.46

**[Table/Fig-2]:** Ligamentum Flavum (LF) thickness as reported in various studies [8,18-27].

thicker than on the right [27]. Furthermore, bilaterally at L5-S1, the LF thicknesses were substantially higher than on the corresponding sides at L4-L5 which was seen in study by Safak AA et al., [28] but contrary to the findings of Kolte VS et al., Horwitz T and Sudhir G et al., [17,21,27].

Abbas J et al., observed that at L3-L4 and L5-S1, significant asymmetry was noted and hypertrophy was observed on the right-side [29]. Sudhir G et al., had findings similar to the above mentioned study [27]. In addition to developmental disruptions, this asymmetry may be a reflection of the differential mechanical stress that the Flavum experiences during its lifetime. It has been speculated that the individuals' side preferences may also be the cause of this asymmetrical mechanical stress. Interestingly, Kolte VS et al., found no difference in LF thickness between measurements taken on the right and left-sides [17]. However, while assessing flavum thickness, both the right and left-sides must be assessed. The mean right and left LF thickness showing asymmetry from various studies has been shown in [Table/Fig-3] [17,21,27,28].

## 2. Anterior Disc Height, Posterior Disc Height and Disc Volume

It was observed that from L1-L2 through L5-S1 level; disc volume, anterior disc height, posterior disc height, had all increased which

Level/Side	Study	Mean LF Thickness (mm)
L4-L5 Right-side	Horwitz T et al., 1939 [21]	3.8
	Sudhir G et al., 2019 [27]	4.5
	Kolte VS et al., 2015 [17]	3.70
	Safak AA et al., 2010 [28]	3.40
L4-L5 Left-side	Horwitz T et al., 1939 [21]	-
	Sudhir G et al., 2019 [27]	4.2
	Kolte VS et al., 2015 [17]	3.84
	Safak AA et al., 2010 [28]	3.46
L5-S1 Right-side	Horwitz T et al., 1939 [21]	3.6
	Sudhir G et al., 2019 [27]	4.8
	Kolte VS et al., 2015 [17]	3.65
	Safak AA et al., 2010 [28]	3.55
L5-S1 Left-side	Horwitz T et al., 1939 [21]	-
	Sudhir G et al., 2019 [27]	4.4
	Kolte VS et al., 2015 [17]	3.78
	Safak AA et al., 2010 [28]	3.61

**[Table/Fig-3]:** Mean right vs left LF thickness showing asymmetry in various studies [17,21,27,28].

was also seen in the study by Sudhir G et al., [27]. Tukeys test showed that the mean anterior disc height at L1-L2 and at L5-S1 were lowest and highest, respectively.

As per Sudhir G et al., there was a statistically significant positive association between flavum hypertrophy and anterior disc height according to Pfirman's grading [27,30]. Even though Pfirman's grading system [30] includes disc height, it is not clear if it refers to anterior or posterior disc height because the disc height is not constant anteroposteriorly. In their series by Munns JJ et al., reported no relationship between the disc height and the LF thickness [31].

## 3. Disc Degeneration

According to the study by Altinkaya N et al., individuals with grades IV to V degeneration had thicker flavum at L2-L3, L3-L4, L4-L5, and L5-S1 levels than in patients with grades I to III degeneration [32]. They inferred that the buckling of the LF into the lumbar spinal canal as a result of disc degeneration is the reason of flavum thickening. Their findings were contrary to the findings of Sakamaki T et al., who had reported no correlation between the flavum thickness and degenerative disc changes [33].

According to Yoshiiwa T et al., there is a substantial positive correlation between LF hypertrophy and increasing disc degeneration severity [26]. The thickness of the LF was observed to be thicker in the grade IV group compared to the grade II and grade III groups. According to Appolonio PR et al., there was no statistically significant association between disc degeneration and flavum thickness [34].

Age exerted a correlation with disc degeneration at all vertebral levels, according to Karavelioglu E et al., [35]. Additionally, at the L4-L5 vertebral level, age was correlated to flavum hypertrophy, facet joint degeneration, disc degeneration, and end plate degeneration, which may imply that age-related degenerative alterations predominate at this level. The findings were similar in studies done by Yoshiiwa T et al., and Karavelioglu E et al., [Table/Fig-4] [26,35].

Vertebral Level	Karavelioglu E et al., 2016 [35]	Yoshiiwa T et al., 2016 [26]	
		<4 mm	≥4 mm
L1-L2	1 mm (1 mm-4 mm)	-	-
L2-L3	1 mm (1 mm-4 mm)	-	-
L3-L4	2 mm (1 mm-4 mm)	-	-
L4-L5	2 mm (1 mm-4 mm)	3 mm (1 mm-4 mm)	4 mm (1 mm-5 mm)
L5-S1	2 mm (1 mm-5 mm)	-	-

**[Table/Fig-4]:** Disc Degeneration and Ligamentum Flavum (LF) thickness in various studies [26,35].

#### 4. Facet Joint

Wang J and Yang X proposed that a coronally oriented L4-L5 facet joint negatively correlated to age ( $r=-0.456$ ,  $p=0.0001$ ), which may help to explain why ageing persons are more likely to develop degenerative spondylolisthesis which is an induced mechanical stress [36]. Imajo Y et al., divided facet joint morphology into four categories: coronalised facet joints were approximately 90°, C-shaped facet joints were slanted at about 45°, and J-shaped facet joints were angled at around 30° [37] and sagittalisated facet junctions showed a reduced facet angle as shown in the [Table/Fig-5] [26,37].

Facet joint morphology at L4-L5 level [37]	Yoshiiwa T et al., [26]
	Average LF thickness (mm)
C-shaped	4.4±1.0
Coronalised	3.9±0.8
J-shaped	4.3±0.8
Sagittalisated	5.0±1.8
p-value	0.24 (Not significant)

[Table/Fig-5]: Facet joint at various vertebral level.

• **Facet joint angle and facet angle asymmetry:** Facet angle increases caudally and confirms the change in the orientation of the facet joints from sagittal plane towards the coronal plane caudally [36]. It also revealed that maximum variation of the facet angle is present at L4-L5 level proved by its widest range among all the levels [Table/Fig-6] [10,13,26,38,39].

Level	Farfan H et al., 1967 [10]	Van Schaik J et al., 1985 [38]	Ahmed AM et al., 1987 [39]	Noren R et al., 1991 [13]	Yoshiiwa T et al., 2016 [26]
L3-L4	-	37.1 (17-57)	-	39.6 (17.6-57)	-
L4-L5	43 (10-70)	48.2 (29.5-75)	52 (12.6-70.3)	48.4 (30-64.5)	40.9±8.4
L5-S1	52 (20-90)	53.1 (36-70)	-	53.9 (29-77.5)	-

[Table/Fig-6]: Mean facet joint angle and observed range (min-max) according to various studies [10,13,26,38,39].

• **Facet tropism:** However, some of them looked into the relationship between facet tropism and flavum thickness. In Sudhir G et al., study observed the highest frequency of facet tropism at the L4-L5 level, they identified a statistically significant positive correlation between facet tropism and flavum thickness at L5-S1 level and not at any other levels [27]. Appolonio PR et al., also found no significant association between the thicknesses of the LF and the presence of tropism at different spinal levels [34].

• **Facet joint degeneration and facet joint Osteoarthritis (OA):** Song Q et al., in their detailed study discussed various aspects of degeneration of the lumbar 3-joint complex [40]. They reported that the mechanical consequences of disc degeneration, includes decrease in disc height, and an increase in facet joint degeneration. Chokshi FH et al., reported that LF thickening can be secondary to facet degenerative changes, independent of disc space narrowing [41]. Analysis of the study conducted by Yoshiiwa T et al., showed that flavum hypertrophy was influenced by facet joint OA and statistically significant relationship between facet joint OA and LF thickening was found [26]. There was a significant correlation between LF thickness and disc degeneration; LF thickness significantly increased with severe disc degeneration [26].

In the study conducted by Karavelioglou E et al., observed that the age related changes (LF thickness, facet joint degeneration, disc degeneration and end plate degeneration) were more prominent at L4-L5 vertebral level [35]. The results of their study suggested that flavum thickening may occur independently or could be associated with facet joint OA especially on the ipsilateral side [35]. There was a significant correlation between LF hypertrophy and facet Joint degeneration/ facet joint OA at each vertebral level [26,35].

#### 5. Lumbar Segmental Motion/Segmental Angulation, Disc Space Widening /Angulation of Disc Space, Vacuum Phenomenon and Lumbar Lordosis

Okpala FO showed how lumbar lordosis was measured using the Lumbo Sacral Joint Angle (LSJA) method [42]. LSJA was the most reliable angular measure of Lumbar Lordosis, followed by the Tangential Radiologic Assessment of Lumbar Lordosis (TRALL) angle, and then, the Lumbosacral Angle (LSA); the Cobbs angle was the least reliable of them all. Statistical analyses were performed by Mann-Whitney U test. The grade system of disc degeneration and facet joint OA were by chi-square test.

Flavum thickening significantly correlated with disc space widening at all vertebral levels and vacuum phenomenon ( $n=7/57$ ) at L4-L5 vertebral level [Table/Fig-7]. Yoshiiwa T et al., observed that age, disc space widening angulation, and facet joint OA were associated with LF thickness. Severe disc degeneration, sagittalisated facet joint orientation, and segmental instability were all linked to the development of LF hypertrophy [26].

Parameter at L4-L5 Vertebral Level	Yoshiiwa T et al., 2016 [26]
Vacuum phenomenon	7 (17.9%) patients
Segmental angulation	7.2°±3.2° (2° to 13°)
Angulation of disc space widening	6.3°±15.1° (-8° to+12°)
Lumbar lordosis	44.9°±11.3° (15° to 73°)

[Table/Fig-7]: Various parameter at L4-L5 vertebral level affecting canal.

#### CONCLUSION(S)

This review shows evaluation of parameters like LF hypertrophy, lumbar segmental instability, lumbar segmental motion, disc degeneration, lumbar spine facet joint orientation, facet joint tropism and facet joint OA leading to LCS. From the review conducted, it was concluded that mechanical stress in the form of disc space widening/angulation of disc space widening or lumbar segmental motion/segmental angulation induces LF hypertrophy and was a major concern for LCS. LF hypertrophy was also associated with age, OA of facet joint at all vertebral levels, and vacuum phenomenon at L4-L5 level.

#### REFERENCES

- [1] Bjerke B, Peer-Reviewed MD. Types of Spinal Stenosis | Spine-health [Internet]. [cited 2023 Jan 23]. Available from: <https://www.spine-health.com/conditions/spinal-stenosis/types-spinal-stenosis>
- [2] Rampersaud YR, Ravi B, Lewis SJ, Stas V, Barron R, Davey R, et al. Assessment of health-related quality of life after surgical treatment of focal symptomatic spinal stenosis compared with osteoarthritis of the hip or knee. *Spine J.* 2008;8(2):296-304.
- [3] Jenis LG, An HS. Spine update: lumbar foraminal stenosis. *Spine.* 2000;25(3):389-94.
- [4] Chahal AS, Mundkur YJ, Sancheti HK, Arora R, Rastogi P. Lumbar canal stenosis. *Paraplegia.* 1982;20(5):288-95.
- [5] Lee BH, Moon SH, Suk KS, Kim HS, Yang JH, Lee HM. Lumbar spinal stenosis: Pathophysiology and treatment principle: A narrative review. *Asian Spine J.* 2020;14(5):682-93. Doi: 10.31616/asj.2020.0472. Epub 2020 Oct 14. PMID: 33108834; PMCID: PMC7595829.
- [6] Winkler P, Zausinger S, Milz S, Buettner A, Wiesmann M, Tonn J. Morphometric studies of the ligamentum flavum: a correlative microanatomical and MRI study of the lumbar spine. *Zentralbl Neurochir.* 2007;68(4):200-04.
- [7] Okuda T, Baba I, Fujimoto Y, Tanaka N, Sumida T, Manabe H, et al. The pathology of ligamentum flavum in degenerative lumbar disease. *Spine.* 2004;29(15):1689-97.
- [8] Yong-Hing K, Reilly J, Kirkaldy-Willis WH. The ligamentum flavum. *Spine.* 1976;1(4):226-34.
- [9] Brailsford JF. Deformities of the lumbosacral region of the spine. *Br J Surg.* 1929;16(64):562-627.
- [10] Farfan H, Sullivan J. The relation of facet orientation to intervertebral disc failure. *Can J Surg J Can Chir.* 1967;10(2):179-85.
- [11] Samartzis D, Cheung JP, Rajasekaran S, Kawaguchi Y, Acharya S, Kawakami M, et al. Is lumbar facet joint tropism developmental or secondary to degeneration? An international, large-scale multicenter study by the AOSpine Asia Pacific Research Collaboration Consortium. *Scoliosis Spinal Disord.* 2016;11:9.
- [12] Weishaupt D, Zanetti M, Boos N, Hodler J. MR imaging and CT in osteoarthritis of the lumbar facet joints. *Skeletal Radiol.* 1999;28(4):215-19.
- [13] Noren R, Trafimow J, Andersson GB, Huckman MS. The role of facet joint tropism and facet angle in disc degeneration. *Spine.* 1991;16(5):530-32.

- [14] Murata K, Akeda K, Takegami N, Cheng K, Masuda K, Sudo A. Morphology of intervertebral disc ruptures evaluated by vacuum phenomenon using multi-detector computed tomography: association with lumbar disc degeneration and canal stenosis. *BMC Musculoskelet Disord*. 2018;19(1):01-13.
- [15] Genevay S, Atlas SJ, Katz JN. Variation in eligibility criteria from studies of radiculopathy due to a herniated disc and of neurogenic claudication due to lumbar spinal stenosis: a structured literature review. *Spine*. 2010;35(7):803.
- [16] Chang SB, Lee SH, Ahn Y, Kim JM. Risk factor for unsatisfactory outcome after lumbar foraminal and far lateral microdecompression. *Spine*. 2006;31(10):1163-67.
- [17] Kolte VS, Khambatta S, Ambiyev MV. Thickness of the ligamentum flavum: correlation with age and its asymmetry-an magnetic resonance imaging study. *Asian Spine J*. 2015;9(2):245.
- [18] Park JB, Chang H, Lee JK. Quantitative analysis of transforming growth factor-Beta 1 in Ligamentum Flavum of lumbar spinal stenosis and disc herniation: *Spine*. 2001;26(21):E492-95.
- [19] Ramsey RH. The anatomy of the ligamenta flava. *Clin Orthop Relat Res* 1976-2007. 1966;44:129-40.
- [20] Brown HA. Enlargement of the ligamentum flavum: a cause of low-back pain with sciatic radiation. *JBJS*. 1938;20(2):325-38.
- [21] Horwitz T. Lesions of the intervertebral disc and ligamentum flavum of the lumbar vertebrae: anatomic study of 75 human cadavers. *Surgery*. 1939;6:410-25.
- [22] Ramani PS, Pery RH, Tomlinson BE. Role of ligamentum flavum in the symptomatology of prolapsed lumbar intervertebral discs. *J Neurol Neurosurg Psychiatry*. 1975;38(6):550-57.
- [23] Fukuyama S, Nakamura T, Ikeda T, Takagi K. The effect of mechanical stress on hypertrophy of the lumbar ligamentum flavum. *J Spinal Disord*. 1995;8(2):126-30.
- [24] Sairyo K, Biyani A, Goel V, Leaman D, Booth R, Thomas J, et al. Pathomechanism of ligamentum flavum hypertrophy: a multidisciplinary investigation based on clinical, biomechanical, histologic, and biologic assessments. *Spine*. 2005;30(23):2649-56.
- [25] Spurling RG, Mayfield FH, Rogers JB. Hypertrophy of the ligamenta flava as a cause of low back pain. *J Am Med Assoc*. 1937;109(12):928-33.
- [26] Yoshiwa T, Miyazaki M, Kawano M, Ikeda S, Tsumura H. Analysis of the relationship between hypertrophy of the ligamentum flavum and lumbar segmental motion with aging process. *Asian Spine J*. 2016;10(3):528.
- [27] Sudhir G, Vignesh Jayabalan S, Gadde S, Venkatesh Kumar G, Karthik Kailash K. Analysis of factors influencing ligamentum flavum thickness in lumbar spine-A radiological study of 1070 disc levels in 214 patients. *Clin Neurol Neurosurg*. 2019;182:19-24.
- [28] Safak AA, Is M, Sevinc O, Barut C, Eryoruk N, Erdogmus B, et al. The thickness of the ligamentum flavum in relation to age and gender. *Clin Anat Off J Am Assoc Clin Anat Br Assoc Clin Anat*. 2010;23(1):79-83.
- [29] Abbas J, Hamoud K, Masharawi YM, May H, Hay O, Medlej B, et al. Ligamentum flavum thickness in normal and stenotic lumbar spines. *Spine*. 2010;35(12):1225-30.
- [30] Pfirrmann CWA, Metzdorf A, Zanetti M, Hodler J, Boos N. Magnetic resonance classification of lumbar intervertebral disc degeneration. *Spine*. 2001;26(17):1873-78.
- [31] Munns JJ, Lee JYB, Espinoza Orias AA, Takatori R, Andersson GBJ, An HS, et al. Ligamentum Flavum Hypertrophy in Asymptomatic and Chronic Low Back Pain Subjects. Chen T wu, editor. *PLOS ONE*. 2015;10(5):e0128321.
- [32] Altinkaya N, Yildirim T, Demir S, Alkan O, Sarica FB. Factors associated with the thickness of the ligamentum flavum: is ligamentum flavum thickening due to hypertrophy or buckling? *Spine*. 2011;36(16):E1093-97.
- [33] Sakamaki T, Sairyo K, Sakai T, Tamura T, Okada Y, Mikami H. Measurements of ligamentum flavum thickening at lumbar spine using MRI. *Arch Orthop Trauma Surg*. 2009;129(10):1415-19. Doi: 10.1007/s00402-009-0849-1. Epub 2009 Mar 12. PMID: 19280205.
- [34] Appolonio PR, Mattar T, Costa AB, Valesin Filho ES, Rodrigues LMR. Thickening of spine ligamentum flavum and facet tropism. *Coluna/Columna*. 2014;13(1):39-42.
- [35] Karavelioglu E, Kacar E, Gonul Y, Eroglu M, Boyaci MG, Eroglu S, et al. Ligamentum flavum thickening at lumbar spine is associated with facet joint degeneration: An MRI study. *J Back Musculoskelet Rehabil*. 2016;29(4):771-77.
- [36] Wang J, Yang X. Age-related changes in the orientation of lumbar facet joints. *Spine*. 2009;34(17):E596-58.
- [37] Imajo Y, Kato Y, Taguchi T. Facet joint morphology of degenerative spondylolisthesis at L4-5. *Spine Spinal Cord*. 2012;25:315-20.
- [38] Van Schaik J, Verbiest H, Van Schaik F. The orientation of laminae and facet joints in the lower lumbar spine. *Spine*. 1985;10(1):59-63.
- [39] Ahmed AM, Hyder A, Burke DL, Chan KH. In-vitro ligament tension pattern in the flexed knee in passive loading. *J Orthop Res*. 1987;5(2):217-30.
- [40] Song Q, Liu X, Chen D-j, Lai Q, Tang B, Zhang B, Dai M, et al. Evaluation of MRI and CT parameters to analyze the correlation between disc and facet joint degeneration in the lumbar three-joint complex. *Medicine (Baltimore)*. 2019;98(40):e17336.
- [41] Chokshi FH, Quencer RM, Smoker WRK. The "Thickened" ligamentum flavum: is it buckling or enlargement? *AJNR Am J Neuroradiol*. 2010;31(10):1813-36.
- [42] Okpala FO. Comparison of four radiographic angular measures of lumbar lordosis. *J Neurosci Rural Pract*. 2018;9(03):298-304.

**PARTICULARS OF CONTRIBUTORS:**

1. Postgraduate, Department of Orthopaedics, Datta Meghe Institute of Higher Education and Research, Wardha, Maharashtra, India.
2. Assistant Professor, Department of Orthopaedics, Datta Meghe Institute of Higher Education and Research, Wardha, Maharashtra, India.
3. Senior Resident, Department of Orthopaedics, Datta Meghe Institute of Higher Education and Research, Wardha, Maharashtra, India.

**NAME, ADDRESS, E-MAIL ID OF THE CORRESPONDING AUTHOR:**

Ankit Jaiswal,  
Gitai House, Shree Krushna Nagar, Opp. Pathya Pustak, Amravati-444604,  
Maharashtra, India.  
E-mail: dhruva.halani@gmail.com

**PLAGIARISM CHECKING METHODS:** [\(Jain H et al.\)](#)

- Plagiarism X-checker: Nov 25, 2022
- Manual Googling: Mar 28, 2023
- iThenticate Software: Apr 04, 2023 (20%)

**ETYMOLOGY:** Author Origin**EMENDATIONS:** 6**AUTHOR DECLARATION:**

- Financial or Other Competing Interests: None
- Was informed consent obtained from the subjects involved in the study? Yes
- For any images presented appropriate consent has been obtained from the subjects. Yes

Date of Submission: **Nov 10, 2022**Date of Peer Review: **Jan 19, 2023**Date of Acceptance: **Apr 21, 2023**Date of Publishing: **Jun 01, 2023**