

## Melanoma of the Ciliary Body: About a Case

R. Zerrouk<sup>1\*</sup>, M. Khmamouche<sup>1</sup>, I. Tarib<sup>1</sup>, Y. Chaoui<sup>1</sup>, Y. Mouzari<sup>1</sup>, F. Elasri<sup>1</sup>,  
K. Reda<sup>1</sup> and A. Oubaaz<sup>1</sup>

<sup>1</sup>Department of Ophthalmology, Military Hospital Mohamed V, University of Medicine and Pharmacy, Rabat, Morocco.

### Authors' contributions

This work was carried out in collaboration among all authors. Author RZ contributed to the photography and writing of the article. Authors MK and IT contributed to the writing of the article. Authors YC, YM and FE contributed to the bibliographic research. Authors KR and AO approved the study. All authors read and approved the final manuscript.

### Article Information

#### Editor(s):

(1) Dr. Krishnangshu Bhanja Choudhury, Assistant Professor, Department of Radiotherapy, R.G. Kar Medical College and Hospital, Kolkata, India.

#### Reviewers:

(1) Niranjan Kc Oral, Shri Dharmasthala Manjunatheshwara University, India.  
(2) Olga Udartseva, Roswell Park Comprehensive Cancer Center, USA.  
Complete Peer review History: <http://www.sdiarticle4.com/review-history/51843>

### Case Study

Received 18 August 2019  
Accepted 22 October 2019  
Published 31 October 2019

### ABSTRACT

Melanoma of the ciliary body is extremely rare. It is rarely diagnosed because of its location and the rarity of its associated symptoms. We report the case of a 35-year-old patient who consults for a decrease in visual acuity in whom ophthalmological examination after pupillary dilatation and with the help of ocular ultrasound and magnetic resonance imaging has made it possible to objectify a melanoma of the ciliary body.

**Keywords:** Melanoma; magnetic resonance imaging; malignant ocular tumour; ultraviolet rays.

### 1. INTRODUCTION

Uveal melanoma is the most common primary malignant ocular tumour in Caucasian adults [1]. Most often, it develops from the choroid or iris. Melanoma of the ciliary body is extremely rare due to its location, size and the rarity of

symptoms reported by patients. Especially since it is most often diagnosed in association with other subtypes of melanoma.

The incidence of uveal melanoma in one year is 5.1 cases per 1 million in the USA [2] and 0.2 to 0.3 cases per 1 million in Africa and Asia [3]. In

\*Corresponding author: E-mail: rachidzerrouk@outlook.com;

contrast, the incidence in Europe is marked by a decrease from North to South, ranging from 2 cases per million in Spain and southern Italy to 8 cases per million in Norway and Denmark [4]. This is related to the protective effect of uveal pigmentation, which is widespread in southern countries with higher exposure to ultraviolet rays.

Choroid melanoma is the most common subtype, unlike ciliary body melanoma, which accounts for just 1 in 10 of all ocular melanomas.

Of all subtypes, iris melanoma is the one with the best prognosis, and ciliary body and anterior choroid have the worst prognosis with a higher mortality rate.

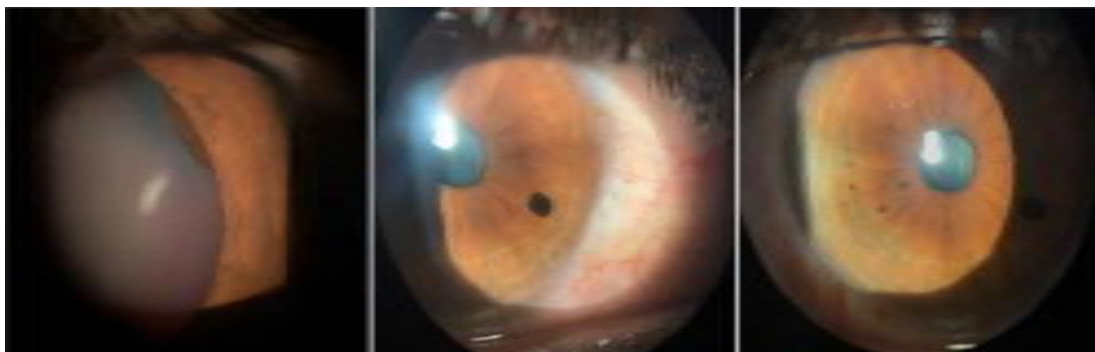## 2. OBSERVATION

This is patient A.K., 35 years old, with no particular history of ocular trauma neither surgery, who presented for a consultation for a visual fog of recent appearance for 2 months, gradually worsening. On admission, the ophthalmological examination of both eyes found on the refraction physiological astigmatism of -0.25 D without ametropia. Visual acuity is 10/10 in OD and 6/10 in OG. The examination of the photo motor reflexes does not find a deficit of the pupillary reflex in light, ocular mobility is good and preserved in the 9 directions of vision. The slit-lamp examination of the OD revealed a brown pigmented iris, with 1 nevus on the middle part of the iris of 1.5 mm on the 5-hour time zone and 4 small nevi from <1mm to 8 am, the rest is normal.

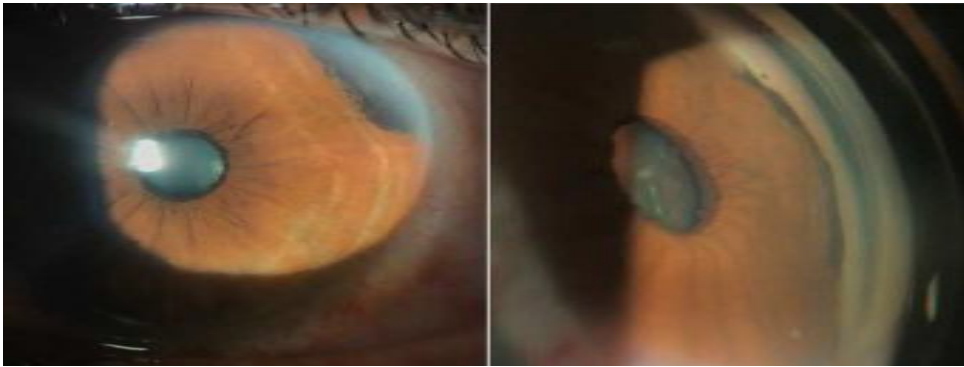The examination of the GC found a healthy conjunctiva, no presence of sentinel vessels, a light and healthy cornea, revealed an iris of the

same brown colour, but with hyperpigmentation of the Irian periphery opposite the ciliary band from 12 h to 2 h, an iris pushed forward opposite this band thus narrowing the depth of the anterior chamber at this level, which was calm and empty, the rest is normal. The IOP was 13mmHg in OD and 14mmHg in OG. The OD gonioscopy revealed a 360° open-angle, and at the level of the GC, a completely closed-angle from 12:00 to 3:00, some synéchie from 3:00 to 5:00, and all AIC structures were visible on the rest from 5:00 to 12:00. During the 3-mirror glass examination, a mass was already visible against the Iranian pigment epithelium corresponding to the repressed portion. This mass appears well rounded, pigmented and covered with a whitish membrane.

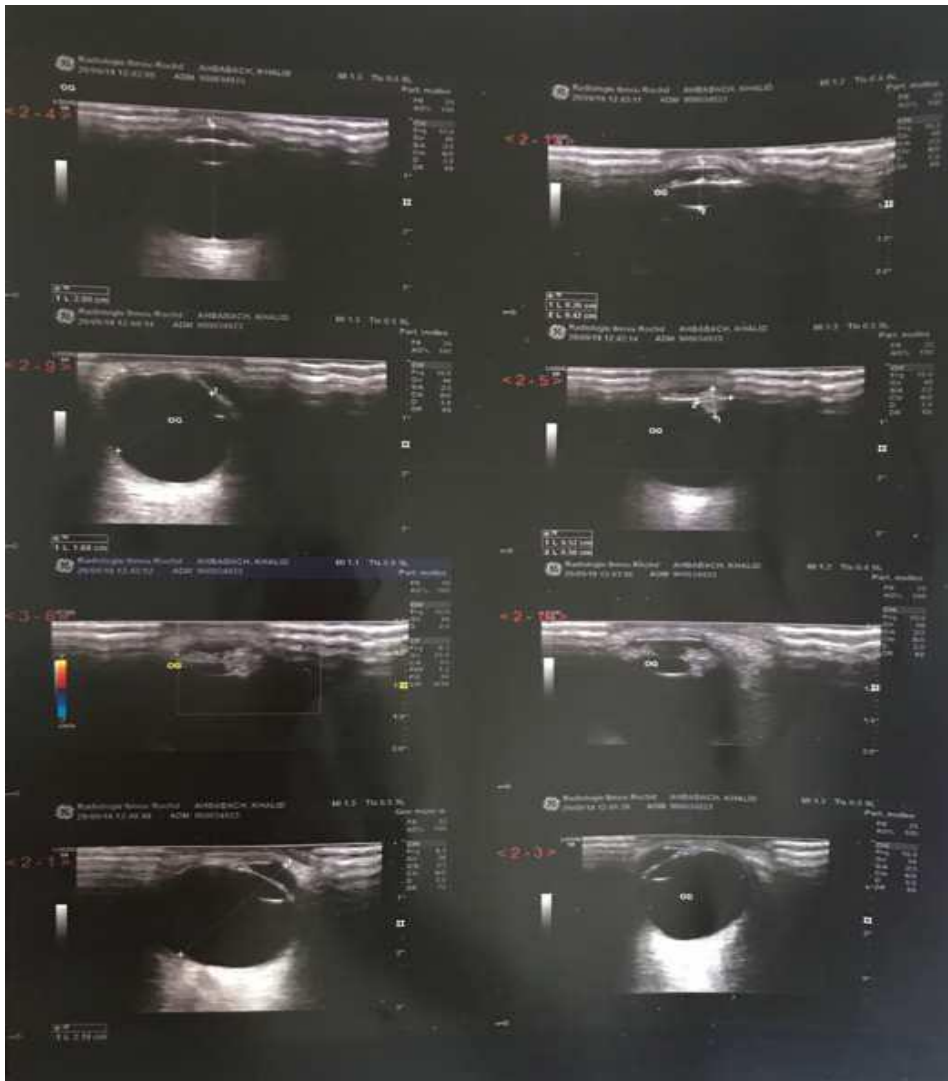
After dilation, the OD examination was strictly normal. At the level of the OG, the mass was visible around the pupil, far from the visual axis, pigmented and well limited, with a phacosclerosis of the lens segment facing it. The examination of the fundus found a healthy papilla with a C/D of 3/10, symmetrical to that of the contralateral eye and a foveolar region with a good macular reflection. A UBM ultrasound was requested, which showed at the level of the left eye a very limited tissue formation of hyperechoic lobed contours measuring 5x5.2 mm without hyper signal Doppler straddling the ciliary body and iris suggestive of melanoma or another epithelial tumor, which on the orbital MRI corresponded to an anomaly in the signal of the left ciliary body that was hypointense on T2 isointense in T1 compared to the vitreous measuring 4x2.5mm and not enhanced by contrast. Diagnosis of ciliary body melanoma was made on both radiological and ophthalmoscopic data.



**Fig. 1. Bio-microscopic examination of the right eye: Brown pigmented iris, with 1nevus on the middle part of the iris of 1.5 mm on the 4-hour time zone, and several small nævi of <1mm between 8 am and 10am**



**Fig. 2. Bio-microscopic examination of the left eye: Hyperpigmentation of the periphery iris is pushed forward against the ciliary band from 12:00 to 2:00, the iris is pushed forward against the ciliary band from 12:00 to 2:00, the iris is pushed forward against the ciliary band. At V3M, the mass is visible against the Irian pigmentary epithelium corresponding to the portion being conveyed. This mass appears well rounded, pigmented and covered a whitish membrane**



**Fig. 3. Ultra biomicroscopy (UBM) of the left eye: Tissue contour formation lobulated well limited hyperechoic lobes measuring 5 x 5.2 mm without hypersignal Doppler on horseback on the ciliary body and the iris**

Following this result, an extension check-up was performed including an NFS, chest X-ray and a Cerebro thoraco abdomino pelvic thoracic CT scan which came back negative.

Given the absence of metastases, the patient's age and superior temporal location, the patient was referred to a specialized radiotherapy centre for the placement of a radioactive disc.

The patients had undergone definitive radical radiotherapy but treatment details and post treatment patient status have not been updated from the referral centre.

### 3. DISCUSSION

Melanoma of the ciliary body is very rare. It is most often extensive and associated with the iris or choroid at the time of diagnosis. This delay in diagnosis is often due to the absence of visual symptomatology for a very long time before the first ophthalmological consultation, which is often concomitant with the presence of local extension or metastasis.

The most commonly reported symptoms are visual fog, as is the case in this patient, this is usually due to astigmatism induced by crystalline changes (dislocation, cataract), myodesopsies, loss of painless visual fields or in the case of severe pain following a glaucoma attack. Sometimes, the diagnosis is made when complications such as exudative retinal detachment following tumour extension to the posterior segment occur.

The poor prognostic factors reported in the literature are tumour dimensions which, when elevated, remain a risk factor independent of location in survival studies following radiotherapy [5,6,7,8]. Ciliary localization, the presence of exudative retinal detachment, macroscopic invasion of the iris root and extra scleral extension are factors of poor prognosis [9].

Our patient had a localized tumour on the ciliary body with iris root discharge, without associated detachment or metastasis. Due to the superior temporal location, the patient was referred to a reference centre abroad for radiotherapy.

### 4. CONCLUSION

Melanoma of the ciliary body is rarely diagnosed due to its location and the rarity of associated

symptoms. This case confirms the importance of the post-dilation examination and the enormous contribution of ocular ultrasound and MRI.

### CONSENT

As per international standard, patient's consent has been collected and preserved by the authors.

### ETHICAL APPROVAL

As per international standard written ethical permission has been collected and preserved by the author(s).

### COMPETING INTERESTS

Authors have declared that no competing interests exist.

### REFERENCES

1. Jovanovic P, Mihajlovic M, Djordjevic-Jocic J, Vlajkovic S, Cekic S, Stefanovic V. Ocular melanoma: An overview of the current status. *Int J Clin Exp Pathol.* 2013;6(7):1230-44. [Published 2013 Jun 15]
2. Uveal melanoma: trends in incidence, treatment, and survival. Singh AD, Turell ME, Topham AK *Ophthalmology.* 2011; 118(9):1881-5.
3. The epidemiological challenge of the most frequent eye cancer: retinoblastoma, an issue of birth and death. Kivelä T *Br J Ophthalmol.* 2009;93(9):1129-31.
4. Incidence of uveal melanoma in Europe. Virgili G, Gatta G, Ciccolallo L, Capocaccia R, Biggeri A, Crocetti E, Lutz JM, Paci E, EURO CARE Working Group. *Ophthalmology.* 2007;114(12):2309-15.
5. Decker M, Castro JR, Linstadt DE, Char D, Petti PL, Quivey JM et al. Ciliary body melanoma treated with helium particle irradiation. *Int J Radiat Oncol Biol Phys.* 1990;19:243-7.
6. Gunduz K, Shields CL, Shields JA, Cater J, Freire JE, Brady LW. Plaque radiotherapy of uveal melanoma with predominant ciliary body involvement. *Arch Ophthalmol.* 1999;117:170-7.
7. McLean IW, Ainsbinder DJ, Gamel JW, McCurdy JB. Choroidal-ciliary body melanoma. A multivariate survival analysis of tumor location. *Ophthalmology.* 1995;102:1060-4.

8. Summanen P, Immonen I, Heikkinen J, Tommila P, Laatikainen L, Tarkkanen A. Survival of patients and metastatic and local recurrent tumor growth in malignant melanoma of the uvea after ruthenium plaque radiotherapy. *Ophthalmic Surg.* 1993;24:82-90.
9. Gambrelle J, Kodjikian L, Rouberol F, Donat D, Duquesne N, Jean-Louis B, Chauvel P, Gérard JP, Romestaing P, Grange JD. Mélanomes uvéaux impliquant le corps ciliaire. Analyse de la survie après protonthérapie et bêta-curiothérapie par ruthénium-106. *Journal Français d'Ophtalmologie*-Janvier. 2004;27(1):40-47.  
DOI:JFO-01-2004-27-1-0181-5512-101019-ART7

© 2019 Zerrouk et al.; This is an Open Access article distributed under the terms of the Creative Commons Attribution License (<http://creativecommons.org/licenses/by/4.0>), which permits unrestricted use, distribution, and reproduction in any medium, provided the original work is properly cited.

*Peer-review history:*

*The peer review history for this paper can be accessed here:*  
<http://www.sdiarticle4.com/review-history/51843>