

Necrotizing Fasciitis of the Breast: A Case Report and Review of Literature

Deepak Khatri^{1*}, V. Shashikala², M. Mallikarjun² and U. D. Manoranjan²

¹*Department of Neurosurgery, SGPGIMS, Raibareilly road, Lucknow, Uttar Pradesh, ZIP – 226014, India.*

²*Department of General Surgery, Bangalore Medical College and Research Institute, Bangalore, India.*

Authors' contributions

This work was carried out in collaboration among all authors. Author DK designed the study, performed the statistical analysis, wrote the protocol and wrote the first draft of the manuscript. Authors VS and MM managed the analyses of the study. Author UDM managed the literature searches. All authors read and approved the final manuscript.

Article Information

Editor(s):

- (1) Dr. Yasushi Shibata, Professor, Department of Neurosurgery, Mito Medical Center, University of Tsukuba, Japan.
- (2) Dr. Georgios Tsoufas, Associate Professor, Aristoteleion University of Thessaloniki, Thessaloniki, Greece.
- (3) Dr. Luis Ricardo Martinhao Souto, Assistant Professor, Surgery division, School of Medical Sciences, Universidade de Marília (UNIMAR), Sao Paulo state, Brazil.

Reviewers:

- (1) Shereen Ahmed Ahmed Qalawa, Port-Said university, Egypt.
- (2) Kazuhiko Sato, Tokyo-West Tokushukai Hospital, Japan.
- (3) K. Ramesh Kumar, K. N. R. University of Health Sciences, S. V. S. Medical College, India.

Complete Peer review History: <http://www.sdiarticle3.com/review-history/47579>

Case Study

Received 02 January 2019
Accepted 04 March 2019
Published 01 May 2019

ABSTRACT

Necrotizing fasciitis of the breast is a rare entity in surgical practice. Since the first report by Shah et al in 2001, only a few cases have been reported worldwide. The rarity of this condition is attested by the fact that there is no definite approach to diagnosis and treatment till date. The etio-pathogenesis is found to be multifactorial. Clinical course is progressive with huge potential for morbidity and mortality due to sepsis.

A 35-years old housewife was referred to our center with 3-weeks history of a progressively enlarging swelling in her right breast. A breast abscess was clinically diagnosed, for which she underwent incision and drainage at a peripheral health center. However, she further developed a large chronic ulcer due to necrosis of the adjacent skin and was subsequently referred to our center.

*Corresponding author: E-mail: docdeepakk@gmail.com;

We managed our case through regular surgical debridement under antibiotic cover and successfully salvaged the breast. Delayed recognition, associated with massive local tissue destruction and systemic toxicity, remains a deadly pitfall in the management of necrotizing fasciitis. Various treatment modalities have been described for this condition, however, an early diagnosis is paramount and a timely aggressive intervention may save the patient's life with good functional outcomes- *a stitch in time saves nine*.

Keywords: Necrotizing fasciitis; breast; surgery; infection.

1. INTRODUCTION

Necrotizing fasciitis (NF) is a potentially fatal soft-tissue infection characterized by progressive necrosis of the fascia and subcutaneous tissues which often leads to a rapid local tissue destruction and a life-threatening sepsis.

In 1952, Dr. B. Wilson first coined the term 'Necrotizing fasciitis' and stated that fascial necrosis is the characteristic feature of this process. [1] Although it can affect any part of the body, the sites most frequently involved include the extremities, the scrotum (Fournier's gangrene), and the perineal region. [2]

Necrotizing fasciitis of the breast is a rare entity in surgical practice. Since the first report by Shah et al in 2001, only a few cases have been reported worldwide. [3] The rarity of this condition is attested by the fact that there is no definite approach to diagnosis and treatment till date. The etio-pathogenesis is found to be multifactorial. Clinical course in progressive with huge potential for morbidity and mortality due to sepsis. However, a timely aggressive surgical intervention may save the patient's life with good functional outcomes- *a stitch in time saves nine*.

1.1 Aim

In this case report, we have discussed our patient who was referred from a peripheral health center with history of right breast abscess leading to Necrotizing fasciitis. Additionally, we have attempted to address the crucial importance of early diagnosis and aggressive surgical intervention in the management of this disease.

2. METHODOLOGY

A single case of necrotizing fasciitis of the breast, who was diagnosed clinically and managed with appropriate surgical therapy, is discussed in this article. A review of pertinent literature on nuances in management of NF is also discussed.

2.1 Presentation of Case

A 35-years old housewife was referred to our center with 3-weeks history of a progressively enlarging swelling in her right breast. A breast abscess was clinically diagnosed, for which she underwent incision and drainage at a peripheral health center. However, she further developed a large chronic ulcer due to necrosis of the adjacent skin and was subsequently referred to

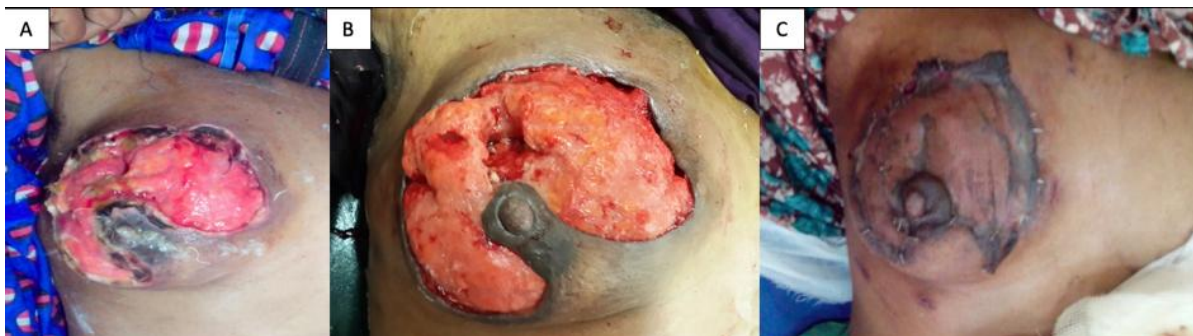

Fig. 1. Clinical photographs of our patient. [A] - at the time of presentation to our hospital showing a large superficial ulcer involving the supero-lateral aspect of right breast with adjacent skin necrosis and slough. Nipple-areolar complex was found spared. Aggressive surgical debridement under antibiotic cover was done regularly. [B] - The ulcer healed well over next 2 weeks with healthy granulation tissue at its bed. [C] - Successful Split-skin graft harvested from right thigh showing good take

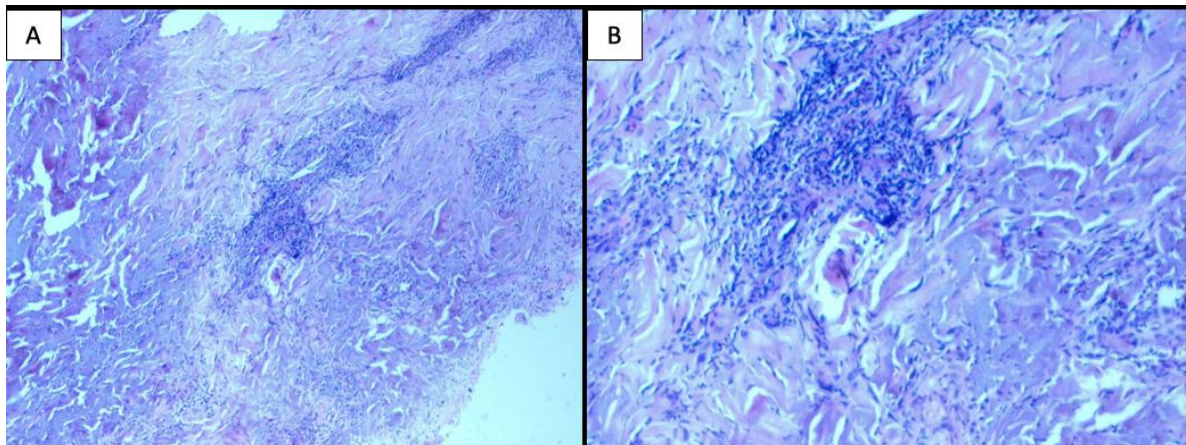


Fig. 2. Histo-pathological examination of the debrided tissue showing hyperplastic surface epithelium with dense fibrin, acute inflammatory cells, dense mononuclear infiltrates with evidence of vasculitis. [A] - at low power-10X and [B] -at high power- 40X. These features were suggestive of a chronic necrotic inflammation

our center. There was no past history of diabetes, trauma or immunosuppression. On clinical examination, patient was stable with no signs of systemic toxicity. A large superficial ulcer measuring about 8 cm x 6 cm in dimension, was seen involving the supero-lateral aspect of her right breast. However, the nipple-areolar complex was found to be spared. [Fig. 1 A] Pus culture examination revealed growth of *Klebsiella sp.* sensitive to Piperacillin-Tazobactam and amikacin. Laboratory examination revealed high erythrocyte sedimentation rate (ESR=80), low hemoglobin (10.2 gm/dL) with a normal total leucocyte count (TLC=9800/mm³) and normal serum creatinine level (0.7 mg/dL). Histopathology results were consistent with chronic necrotizing inflammation of the breast parenchyma with dense mononuclear infiltrates and evidence of vasculitis. [Fig. 2] Regular wound debridement was done under coverage of sensitive antibiotics. Wound responded well with healthy granulation tissue over next 2-weeks of clinical course [Fig. 1B] and a split-skin grafting was done with good clinical outcome [Fig. 1C].

3. DISCUSSION

The clinical description of NF by Hippocrates in the fifth century and the confederate army surgeon, Joseph Jones, in the American Civil War, 1871 are no different from the presentation in modern times. [4,5]

NF of the breast usually occurs unilaterally, although bilateral NF breast have been reported. [6] Predisposing factors for the development of NF include preceding mastitis or breast abscess,

history of trauma, minor cuts and burns, injection drug use, insect bites, puerperium, lactation and the condition is frequently encountered in patients with diabetes mellitus (DM), peripheral vascular disease (PVD) or who are immunosuppressed.

Sometimes, it may occur following few surgical procedures such as core biopsy of breast, surgical debridement of an inflammatory breast lesion, quadrantectomy, or may even be idiopathic [6].

Histopathologically, the type of necrosis frequently seen in breast is a coagulative necrosis or dry type of necrosis. Recently, several clinical subtypes of NF have been described with hyperacute and sub-acute variants [7,8]. Predominantly, Type-1 NF is polymicrobial, commonly including gram-positive & gram-negative anaerobes and are found associated with DM, or PVD. Type-2 NF is a monomicrobial infection, most frequently Group-A beta hemolytic streptococci (*S. pyogenes*), either alone or in association with *S. aureus*. Type-3 NF (common in Asia) is caused by gram-negative monomicrobial infection, including marine-related organisms such as *Klebsiella*, *Enterobacteriaceae*, *Vibrio* species. While, Type-4 NF is caused by fungal infections and most commonly follow traumatic wound and burns. [9] Giuliano et al showed that 77% of patients had a combination of facultative organisms and anaerobes, and a synergistic action between the two could explain the fulminant course of the disease [10]. The pus culture in our patient showed monomicrobial

growth of *Klebsiella* sp. suggesting a diagnosis of Type-3 NF.

Pain out of proportion to the visible skin changes, swelling, and a warm overlying skin may be the only presenting complaints. Owing to a thick breast tissue between the deep fascia and the skin, cutaneous signs may not be apparent until the disease is well advanced. Cutaneous features of NF, as the disease evolves from early to intermediate & late stages (eg: Large haemorrhagic bullae, skin necrosis, fluctuance, sensory deficits & crepitus) have previously been well-identified.

The diagnosis of NF is mainly clinical. Early cutaneous signs such as erythema, local warmth, skin induration, and edema are non-specific which makes early recognition very difficult. This condition has variously been misdiagnosed as cellulitis, abscess, and even inflammatory breast cancer [11,12]. A high index of suspicion is, therefore, of paramount importance.

Imaging techniques such as ultrasound, Magnetic resonance imaging (MRI) and frozen section biopsies, have been reported to be of value in the early recognition of necrotizing fasciitis. [13] However, availability and cost often limit the routine use of these tests.

Hanif et al have described sonographic features of the disease as marked subcutaneous edema, diffuse edema of the glandular tissue and a deeper fluid collection with small bright foci within, suggestive of micro-bubbles of gas. [13]

Diagnostic scoring systems have been developed recently to help in early recognition of the disease are particularly helpful in the assessment of suspicious cases. They include the laboratory risk indicator for necrotizing fasciitis (LRINEC) score which helps to differentiate NF from other soft-tissue infections and Transcutaneous tissue oxygen saturation monitoring with Near-Infrared Spectroscopy (NIRS) [8,14].

Surgical debridement is paramount, and must be performed early and aggressively. It should not be delayed if the patient is in septic shock. The robust blood supply of the breast makes salvage possible if this condition is recognized early. However, extensive involvement often necessitates mastectomy [15].

The extent of infection can be delineated by bluntly probing the wound, followed by

systematic excision. Wong et al classified the infected skin into Zone 1 - Necrotic tissue, Zone 2 - Infected but potentially salvageable soft tissue, and zone 3 - Non-infected skin. Zone 1 is completely excised. Zone 2 is meticulously assessed and cut back as necessary to remove nonviable tissue until healthy, uninfected tissue with good bleeding is encountered. Zone 3 is left alone [16,17].

The aim of surgery must be to remove all infected tissue at the first debridement. This halts the progression of the fasciitis and minimizes unnecessary returns to the operating room.

After the clearance of devitalized tissue, with healthy granulation tissue bed, reconstructive measures (eg: split-skin graft) aimed at skin closure can be attempted under broad-spectrum antibiotic coverage. We have successfully utilized a split skin graft harvested from her right thigh to cover the raw breast with good cosmetic outcome.

A delayed clinical diagnosis, lack of awareness among patients, poor socio-economic factors, lack of adequate surgical facilities and delayed referrals to higher center may lead to complications. Delayed presentation can potentially cause massive local tissue loss, severe sepsis with Multi-organ dysfunction syndrome, adding to a preventable mortality. Therefore, a timely diagnosis and aggressive surgical approach is crucial in managing these patients.

4. CONCLUSION

Necrotizing fasciitis of the breast is a rare, devastating clinical condition with huge potential for morbidity and mortality. Delayed recognition of NF remains a deadly pitfall in the management. With a better understanding of the clinical manifestations, potential use of recent diagnostic adjuncts and a timely aggressive surgical intervention, we may avoid a mastectomy and save a life.

CONSENT AND ETHICAL APPROVAL

As per university standard guideline participant consent and ethical approval has been collected and preserved by the authors.

COMPETING INTERESTS

Authors have declared that no competing interests exist.

REFERENCES

1. Wilson B. Necrotizing fasciitis. *Am Surg.* 1952;18:416.
2. Kuzaka B, Wróblewska MM, Borkowski T, et al. Fournier's gangrene: Clinical presentation of 13 cases. *Med Sci Monit.* 2018;24:548-555. Published 2018 Jan 28. DOI: 10.12659/MSM.905836
3. Shah J, Sharma AK, O'Donoghue JM, Mearns B, Johri A, Thomas V. Necrotising fasciitis of the breast. *Br. J. Plast. Surg.* 2001;54:67.
4. Cocanour CS, Chang P, Huston JM, et al. Management and novel adjuncts of necrotizing soft tissue infections. *Surg Infect (Larchmt).* 2017;18(3):250-272.
5. Mittal S, Singh B, Mittal R, Singh K. A prospective study of cases with necrotising fasciitis: Our experience at a tertiary care teaching hospital. *Int Surg J.* 2017;4:3326-9.
6. Angarita FA, Acuna SA, Torregrosa L, Tawil M, Sánchez EF, Heilbron O, Domínguez LC. Bilateral necrotizing fasciitis of the breast following quadrantectomy. *Breast Cancer.* 2014;21(1):108-14. DOI: 10.1007/s12282-010-0219-4. [Epub 2010 Sep 3. PubMed PMID: 20814771]
7. Wani I, Bakshi I, Parray FQ, Malik AA, Wani RA, Shah M, Husasin I, Malik A, Wani S, Syed W. Breast gangrene. *World J Emerg Surg.* 2011;6:29. DOI: 10.1186/1749-7922-6-29 [PubMed PMID: 21854557; PubMed Central PMCID: PMC3173289]
8. Wong CH, Wang YS. The diagnosis of necrotizing fasciitis. *Curr Opin Infect Dis. Review.* 2005;18(2):101-6. [PubMed PMID: 15735411]
9. Machado NO. Necrotizing fasciitis: The importance of early diagnosis, prompt surgical debridement and adjuvant therapy. *North American Journal of Medical Sciences.* 2011;3(3):107-118. Available: <https://doi.org/10.4297/najms.2011.3107>
10. Giuliano A, Lewis F Jr, Hadley K, Blaisdell FW. Bacteriology of necrotizing fasciitis. *Am J Surg.* 1977;134:52-7.
11. Rajakannu M, Kate V, Ananthakrishnan N. Necrotizing infection of the breast mimicking carcinoma. *Breast J.* 2006;12(3):266-7. [PubMed PMID: 16684327]
12. Konik RD, Cash AD, Huang GS. Necrotizing fasciitis of the breast managed by partial mastectomy and local tissue rearrangement. *Case Reports Plast Surg Hand Surg.* 2017;4(1):77-80. [Published 2017 Aug 17] DOI: 10.1080/23320885.2017.1364970
13. Hanif MA, Bradley MJ. Sonographic findings of necrotizing fasciitis in the breast. *J Clin Ultrasound.* 2008;36(8):517-9. DOI: 10.1002/jcu.20492 [PubMed PMID: 18454477]
14. Wong CH, Khin LW, Heng KS, Tan KC, Low CO. The LRINEC (Laboratory Risk Indicator for Necrotizing Fasciitis) score: A tool for distinguishing necrotizing fasciitis from other soft tissue infections. *Crit Care Med.* 2004;32(7):1535-41. [PubMed PMID: 15241098]
15. Fayman K, Wang K, Curran R. A case report of primary necrotising fasciitis of the breast: A rare but deadly entity requiring rapid surgical management. *Int J Surg Case Rep.* 2017;31:221-224.
16. Wong CH, Yam AK, Tan AB, Song C: Approach to debridement in necrotizing fasciitis. *Am J Surg.* 2008;196:e19-e24.
17. Wong CH, Tan BK. Necrotizing fasciitis of the breast. *Plastic and Reconstructive Surgery.* 2008;122(5):151e-152e.

© 2019 Khatri et al.; This is an Open Access article distributed under the terms of the Creative Commons Attribution License (<http://creativecommons.org/licenses/by/4.0>), which permits unrestricted use, distribution, and reproduction in any medium, provided the original work is properly cited.

Peer-review history:
The peer review history for this paper can be accessed here:
<http://www.sdiarticle3.com/review-history/47579>